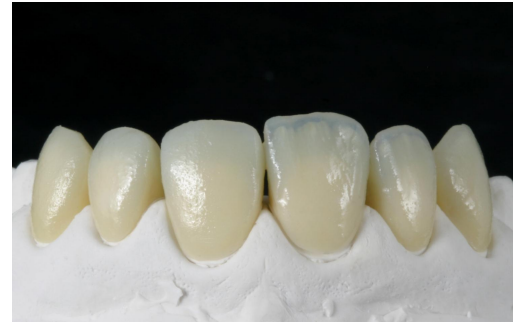
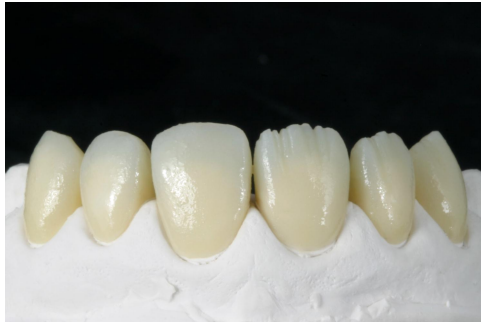
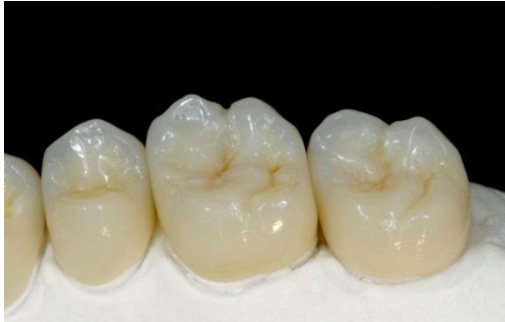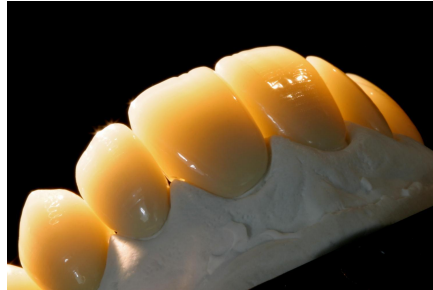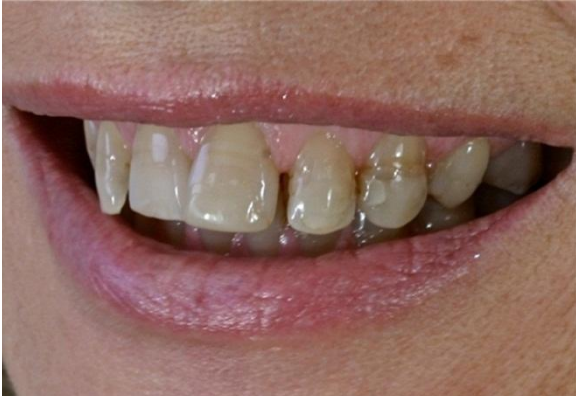SR Nexco Clinical Cases



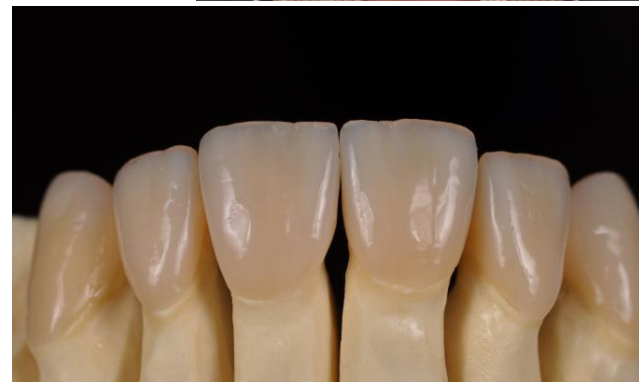
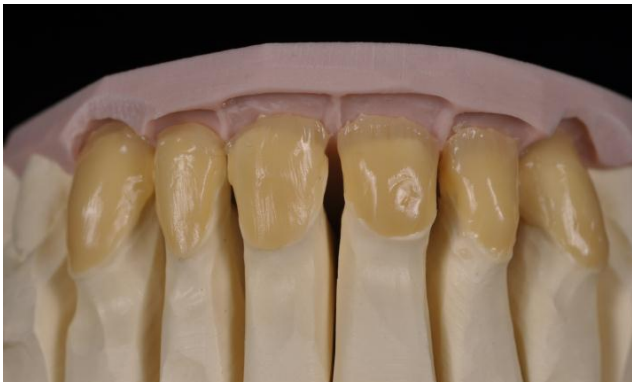

Single crowns, full arch - Robert Zubak, Slovakia



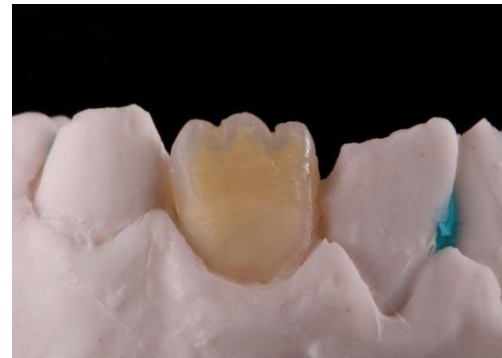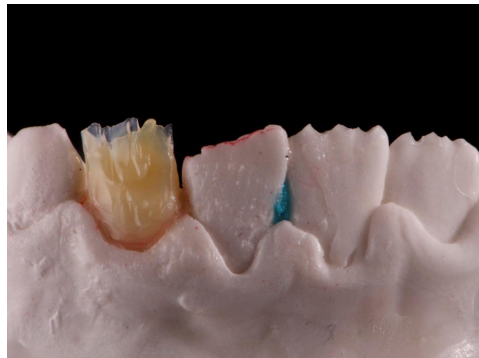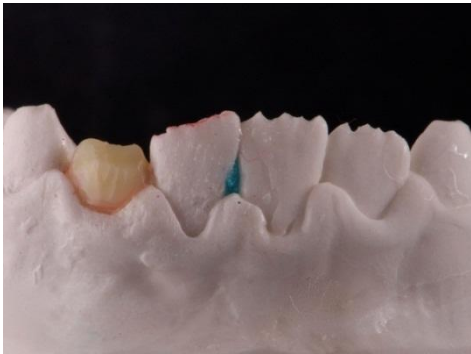


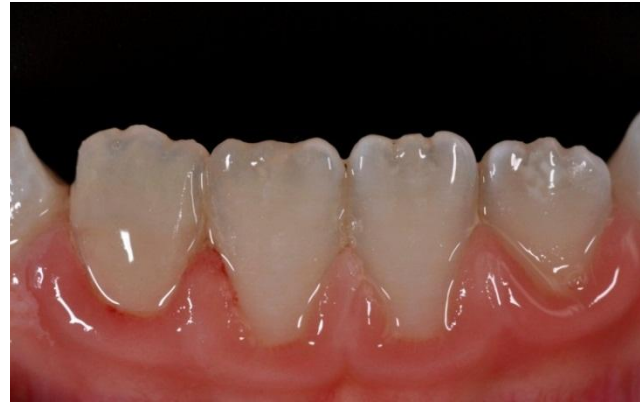
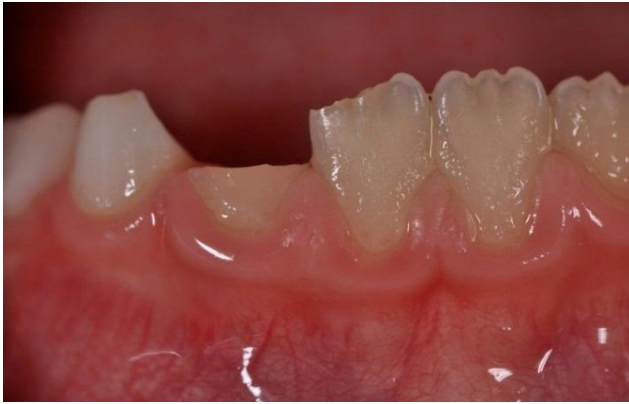Veneers - Annette v. Hajmasy, Germany



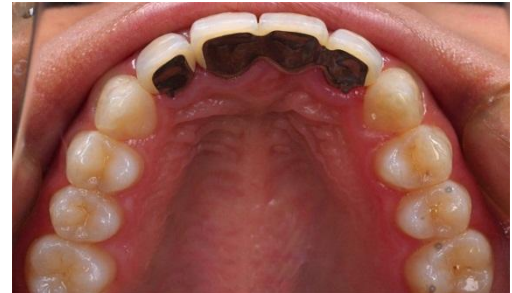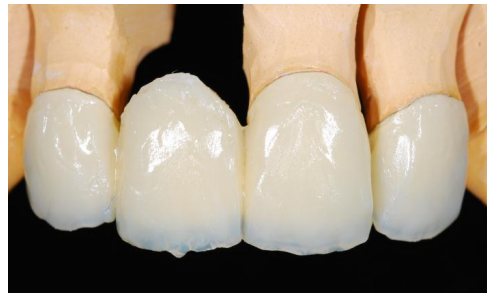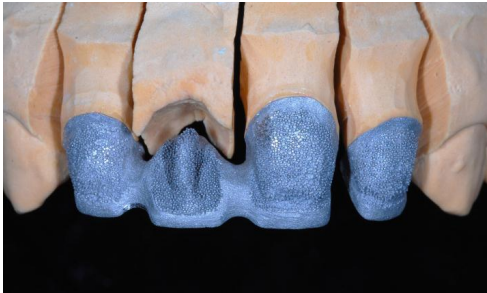


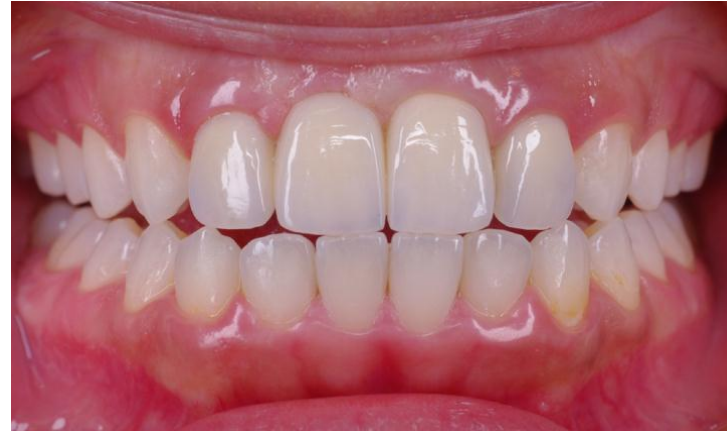
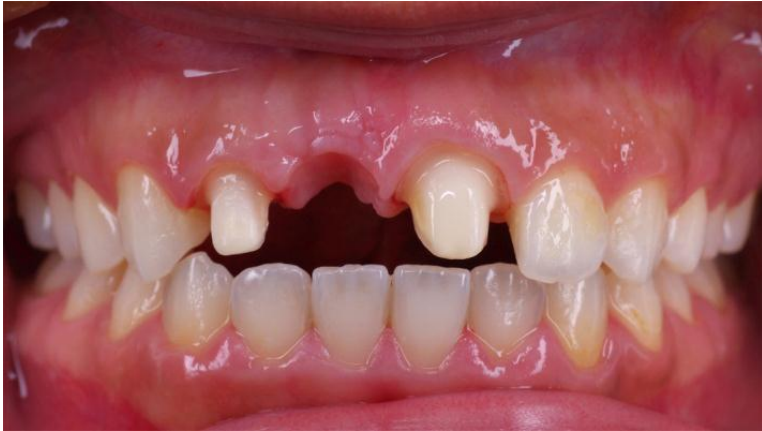Anterior Onlay - H el ene & Didier Creszenzo, France



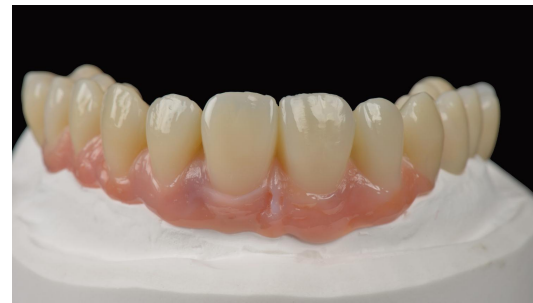
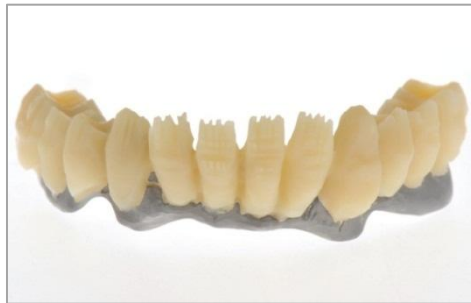
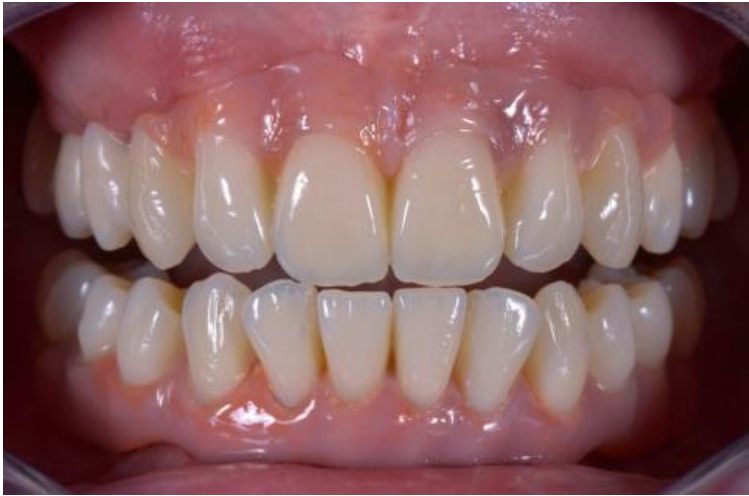
Metal-supported bridge - Dr. A. Shinya, Japan



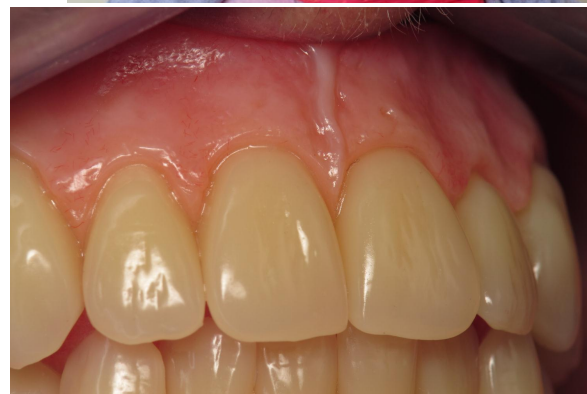
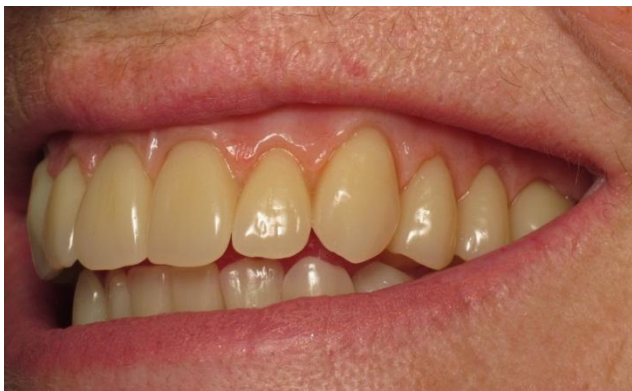
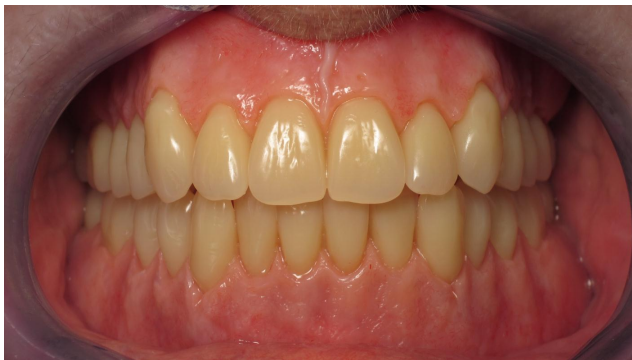Implant case - Hans Joachim Lotz, Germany



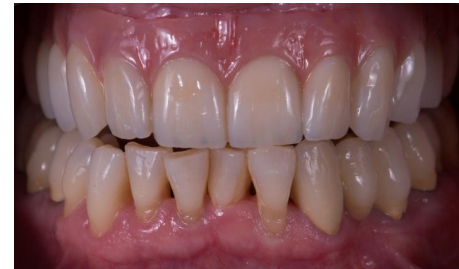
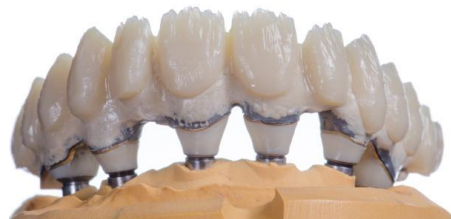
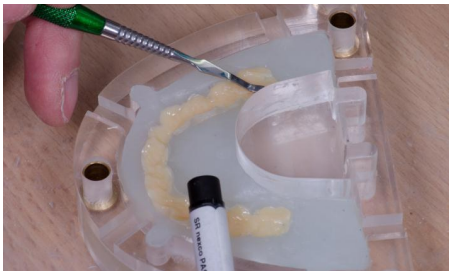Individualized Prosthesis - Yves Gastard, France





Implant case - Christian Hannker, Germany





Implant case - ZTM Cesare Ferri, Italy

