

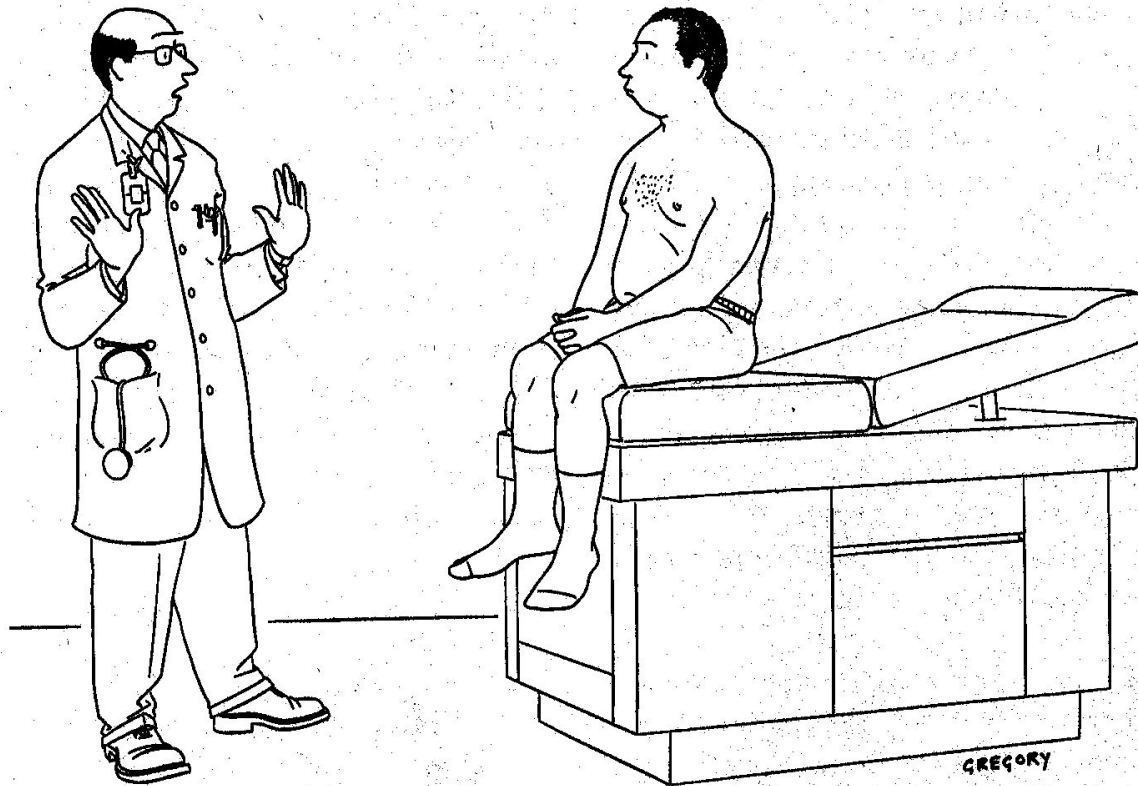
MUSCULOSKELETAL EXAM

- 37M people have some form of arthritis-you will have lots of patients
- Rheumatology- needs more than just a few good physicians- needs a lot of physicians
- Value of the H&P- a truism...if you don't know 90% of the time or better what the patient has by the end of the HPI..you are in trouble

Things you **must** Do

- Is the pain worse on weight bearing?
- Is the worst pain and stiffness present upon arising?
- What drugs have you tried, what dose and what happened?
- Always do bilateral assessments of joints

Make the patient focus!



"Whoa—way too much information."

How **not** to write your history

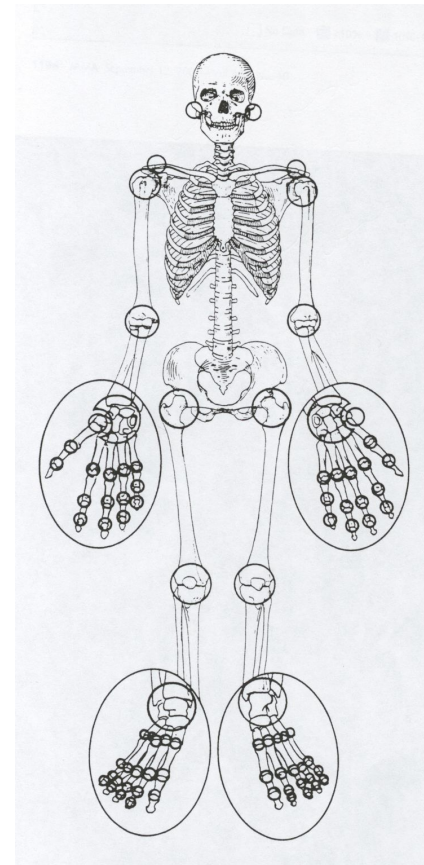


Sunday 3:00 p.m.

What do you do on Sunday if you can ride a cloud?
A slow hour passes while having a loose wind have
had blown. By the way, please teach it somewhere.

RECORDING THE EXAM

- In the real world-”BJM are normal”or “all joints:ROM intact”
- Can use either a table format or Stick diagram/template
- STL system is 0-4 with 4 being the worst possible and 0 is normal
- Worst is **maximal** swelling, **severe** tenderness and **complete** loss of motion
- Simply state whether fluid is present or not

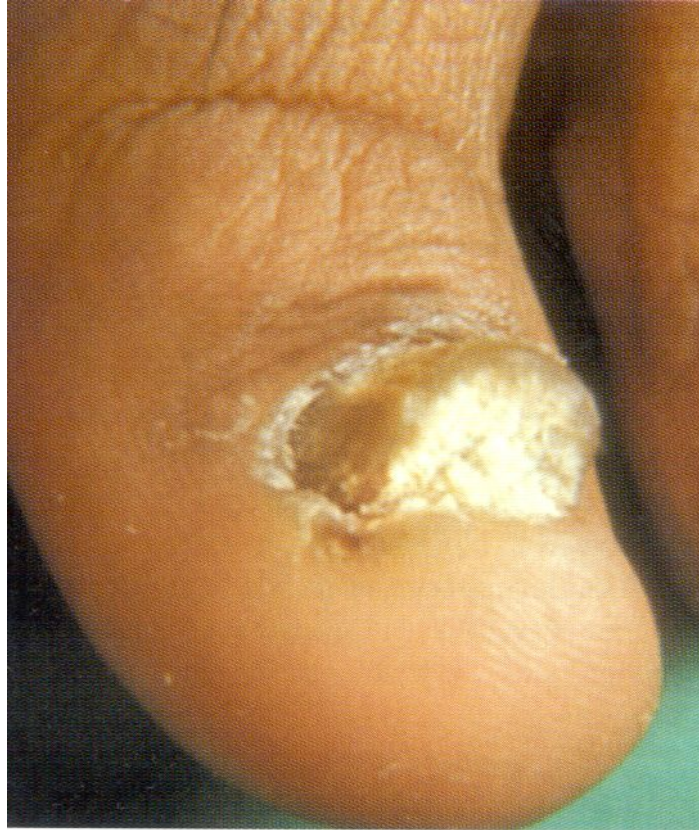

BONDING

“Our hands are central to our psychology as they continually switch between executive, exploratory and expressive activity”

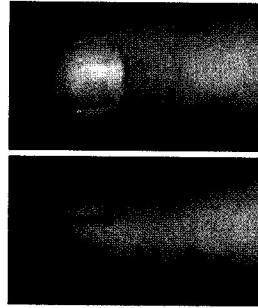
UPPER BODY

- Nails

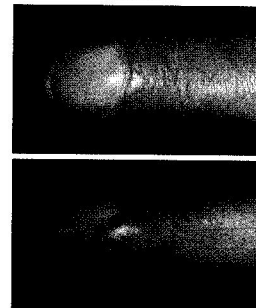


A Appearance

Normal

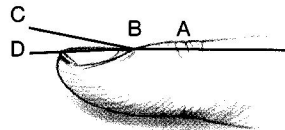


Clubbed

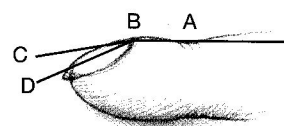


B Nail-fold Angles

Normal

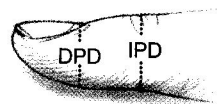


Clubbed




C Phalangeal Depth Ratio

Normal

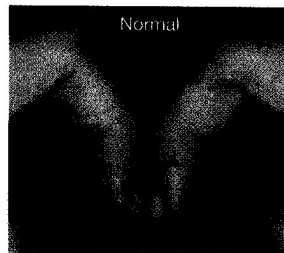


Clubbed

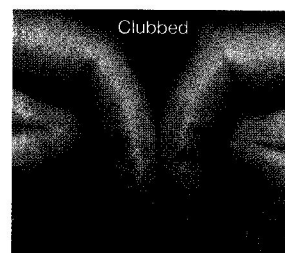


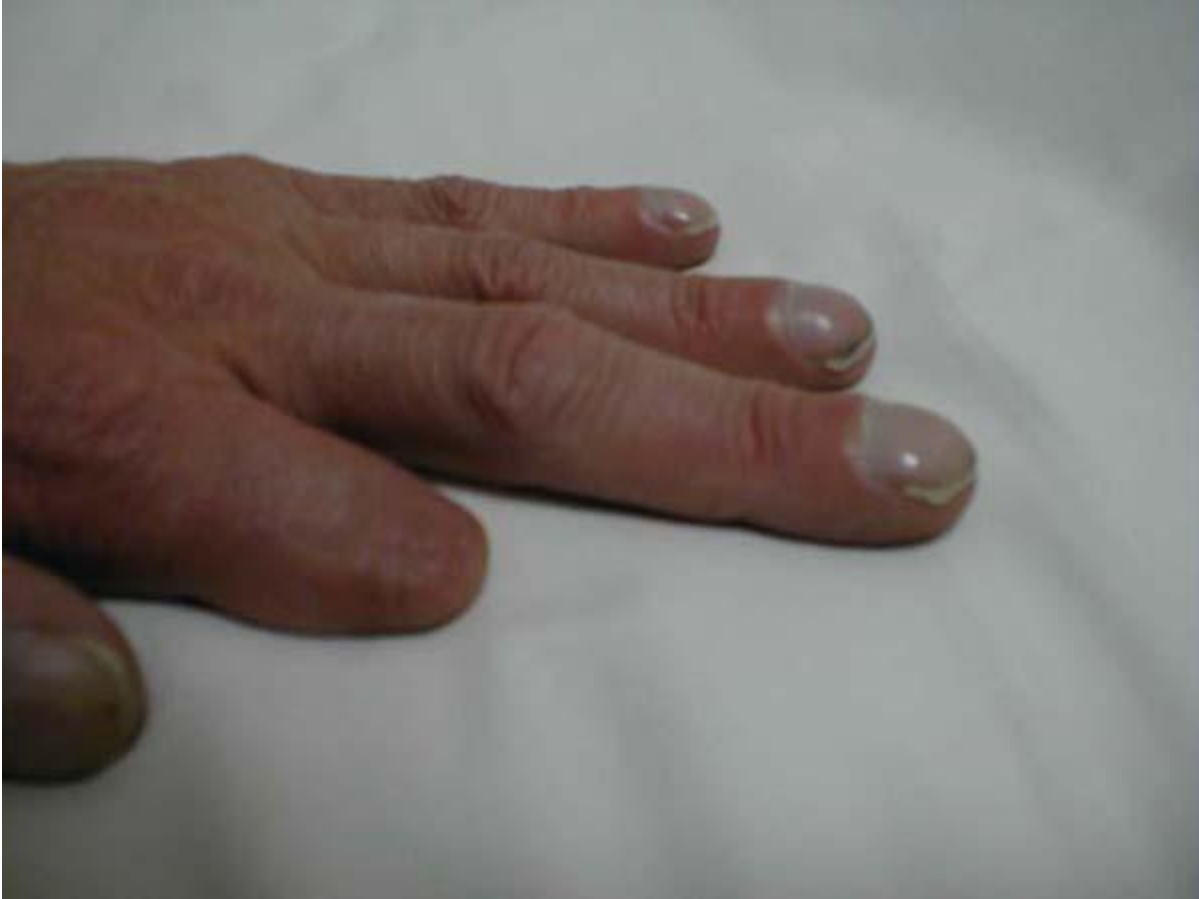D Schamroth Sign

Normal



Clubbed





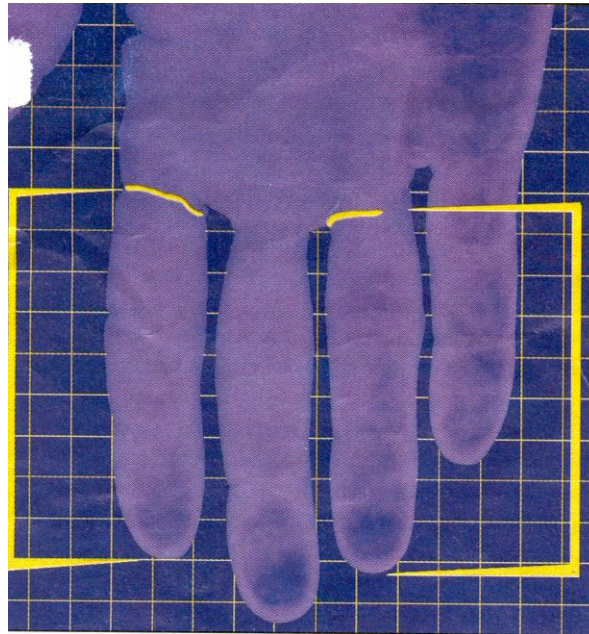
UPPER BODY

- Nails
- Palms, Hands..... Grip strength and “knuckle sign” are very helpful.

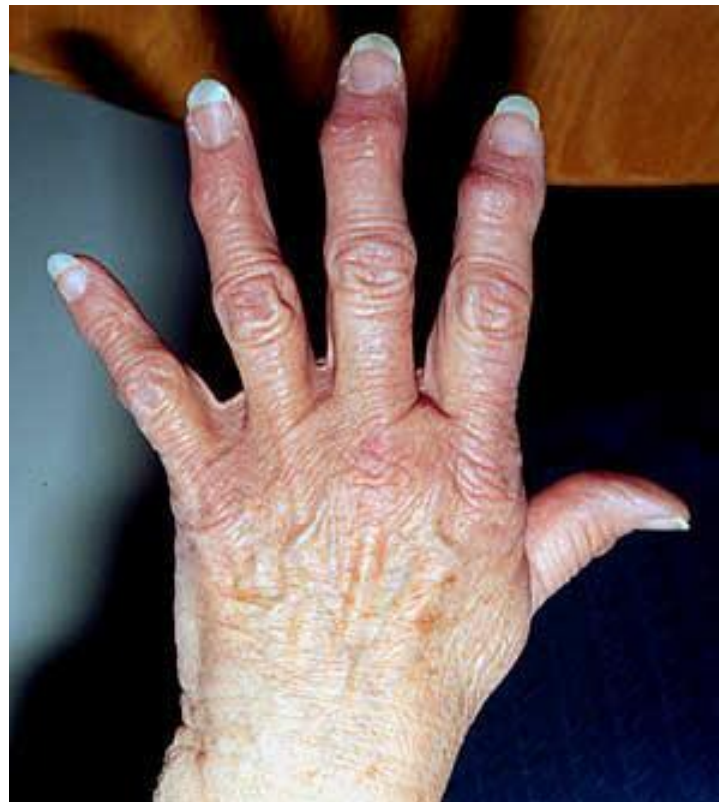Depression



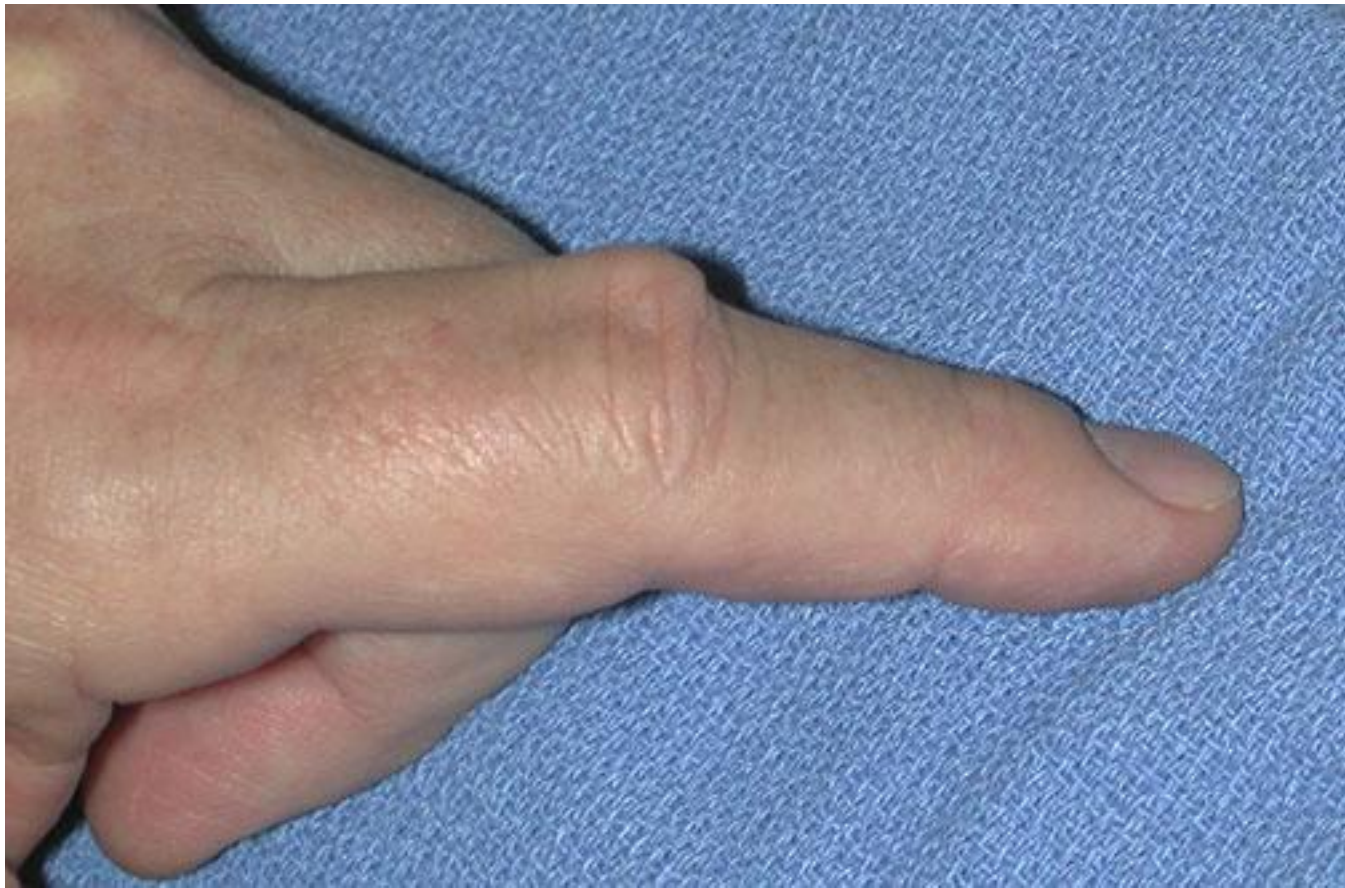More or less susceptible to myocardial infarction?



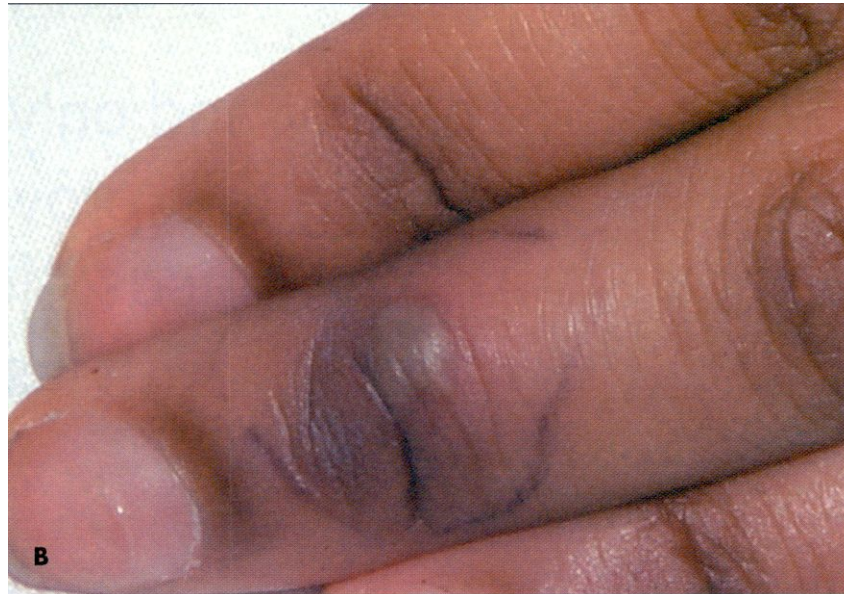Heberden's Nodes



Bouchard's Nodes



Clue to an infectious arthritis



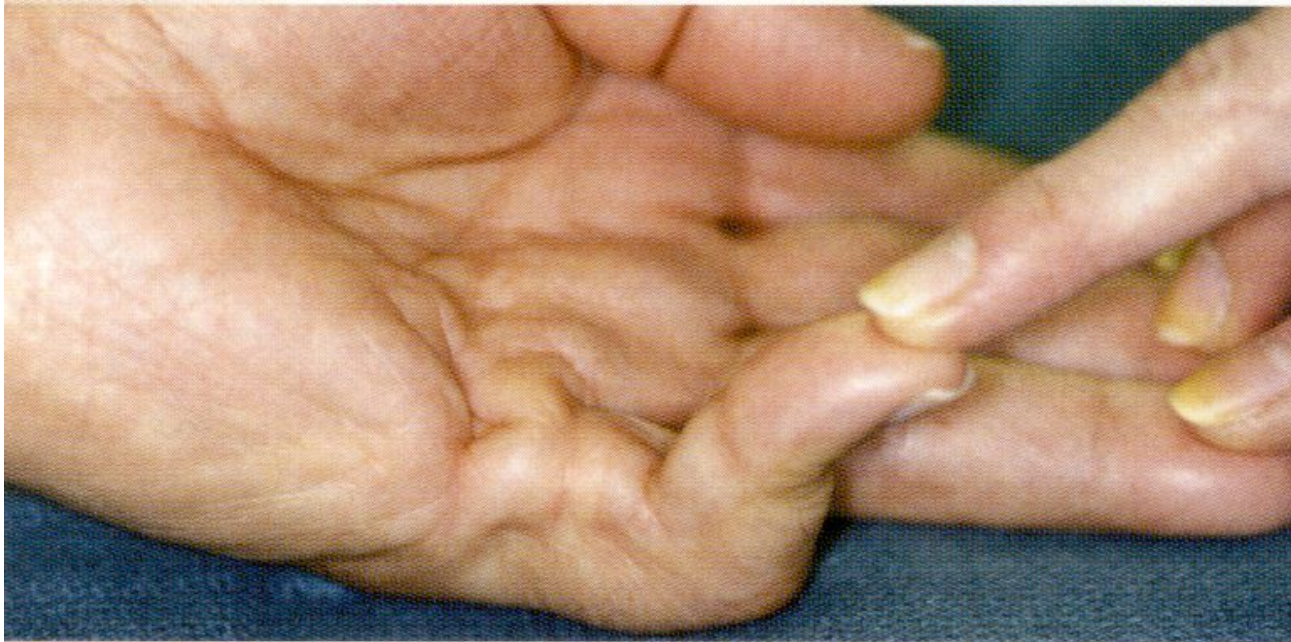
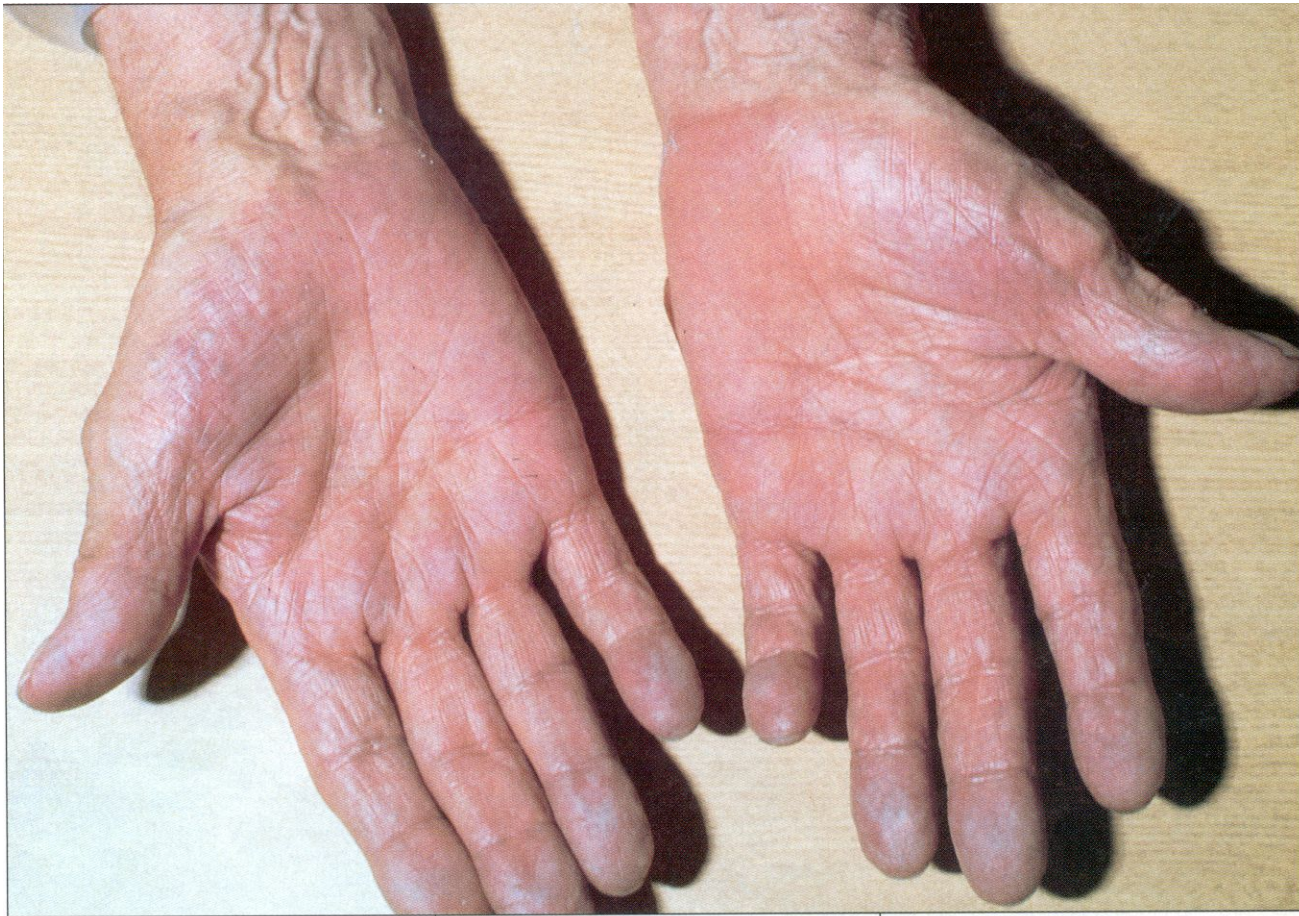
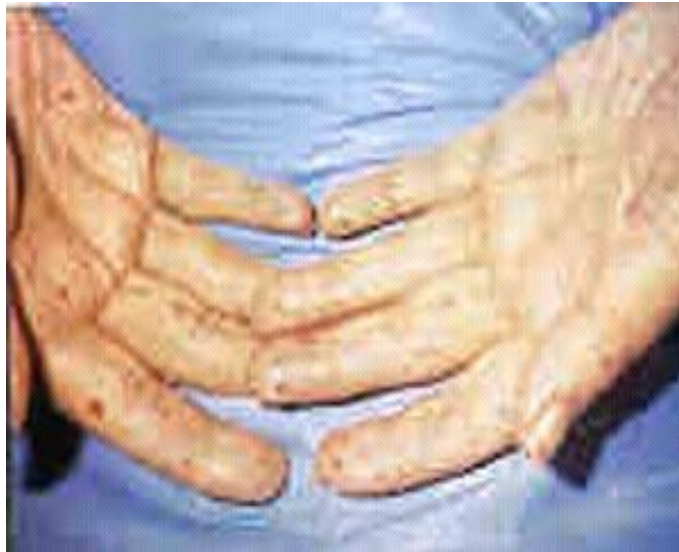FIGURE 1. Dupuytren disease

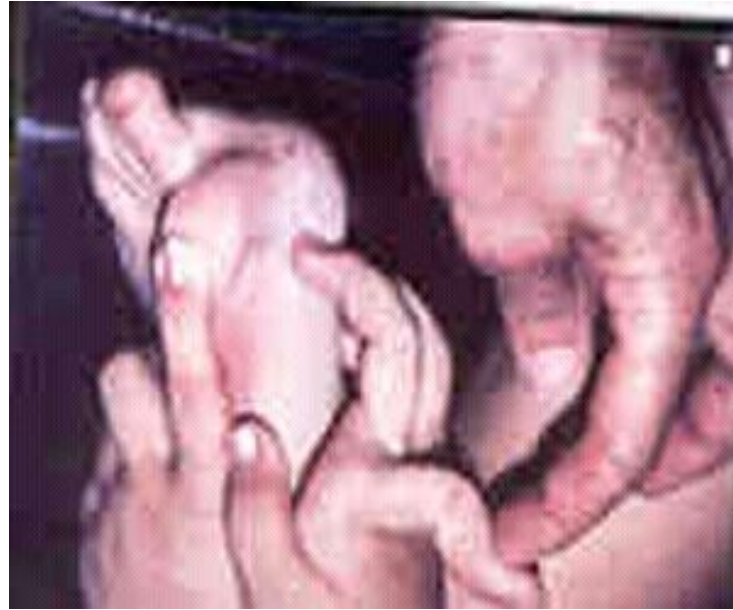Palmar Erythema



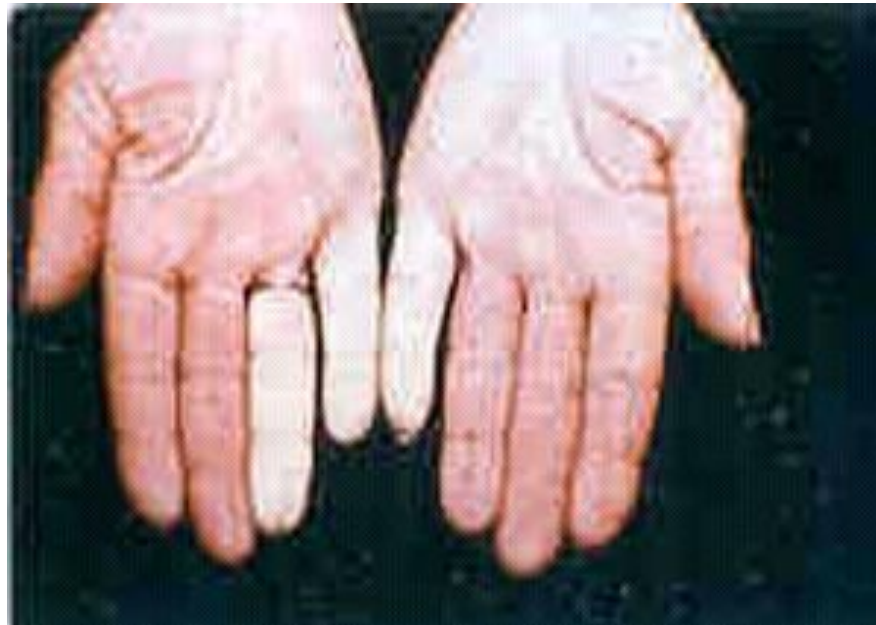telangiectasia



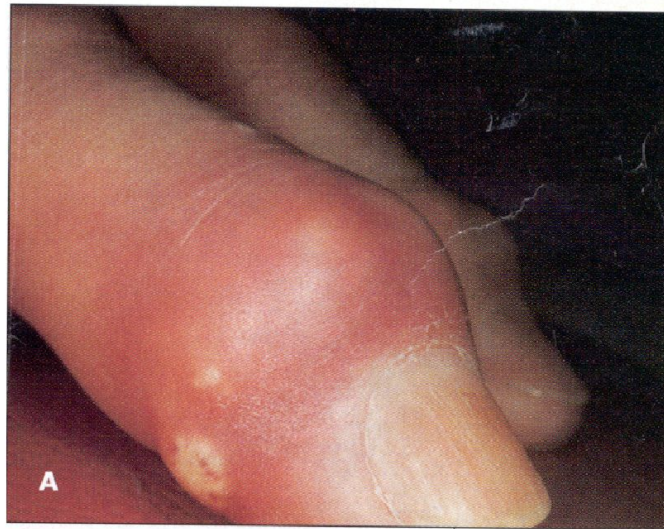Double Jointed



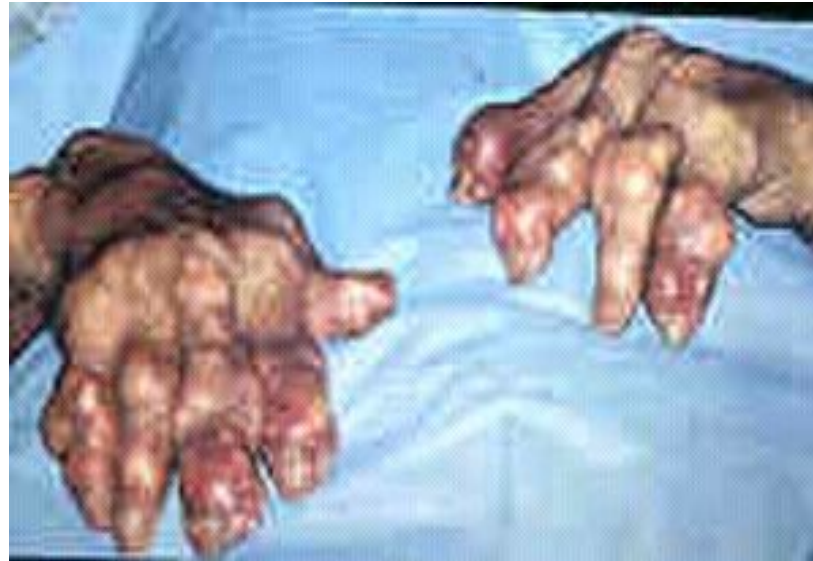This Patient should stop what?



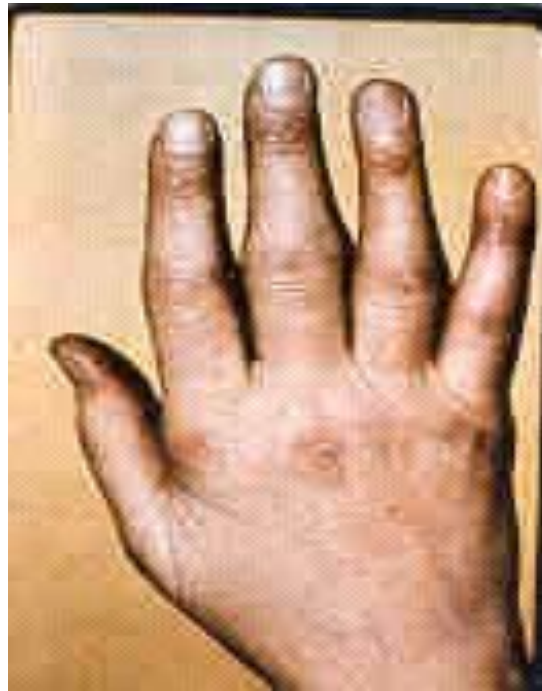What are the yellow nodules?



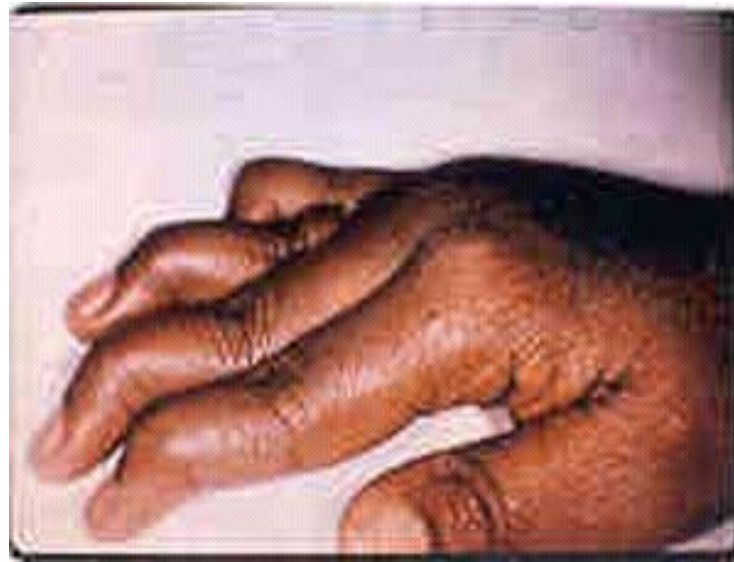What drug should this patient have been on?

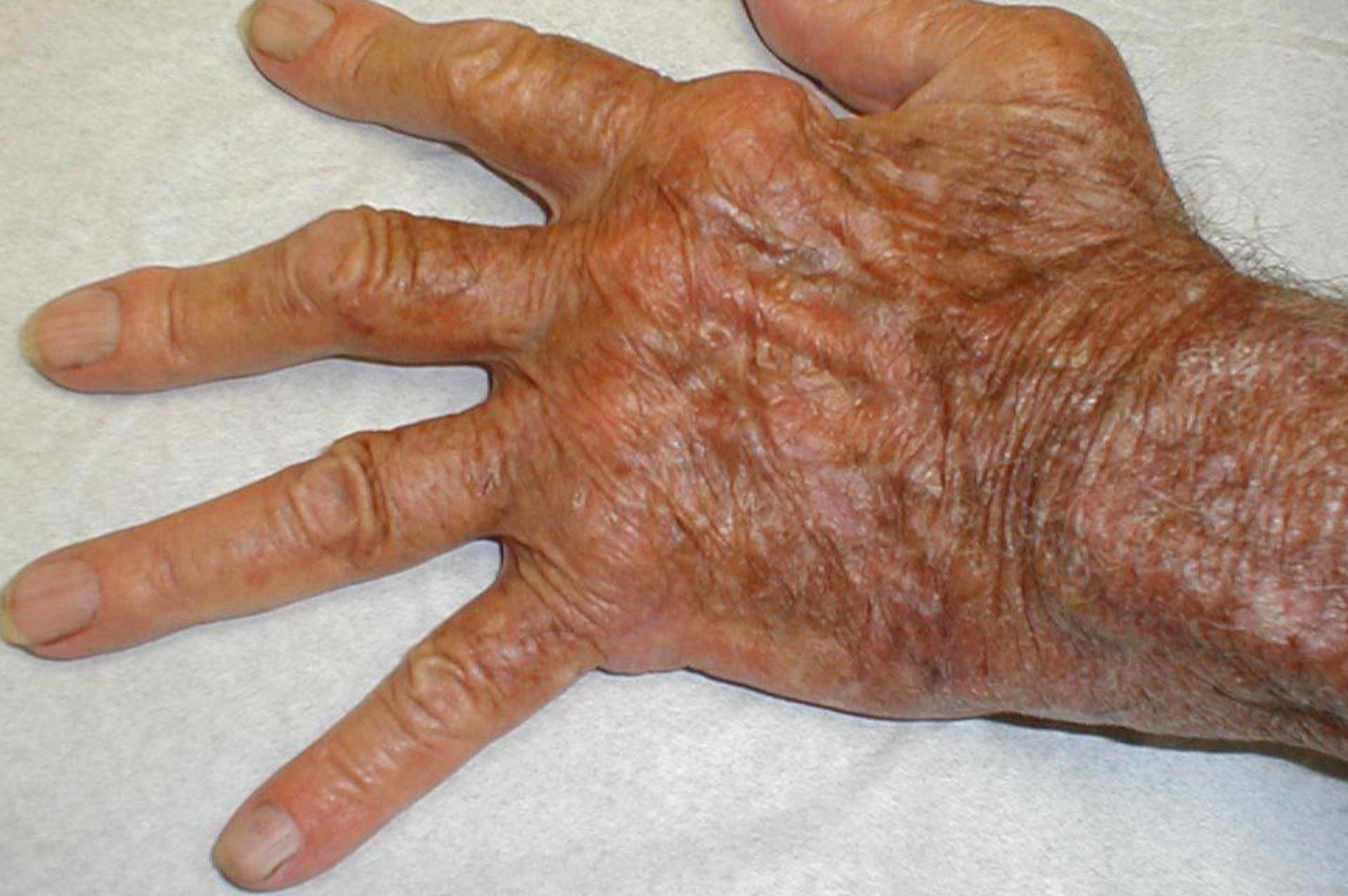

Synovitis



Rheumatoid arthritis

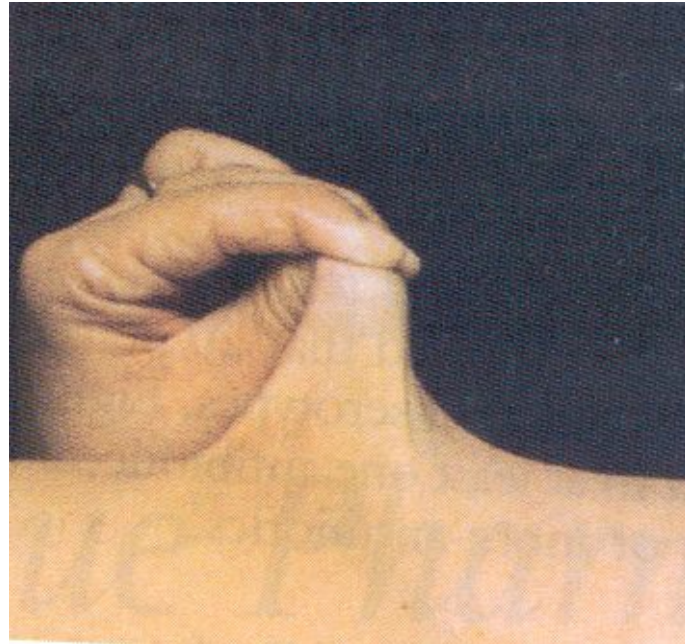




UPPER BODY

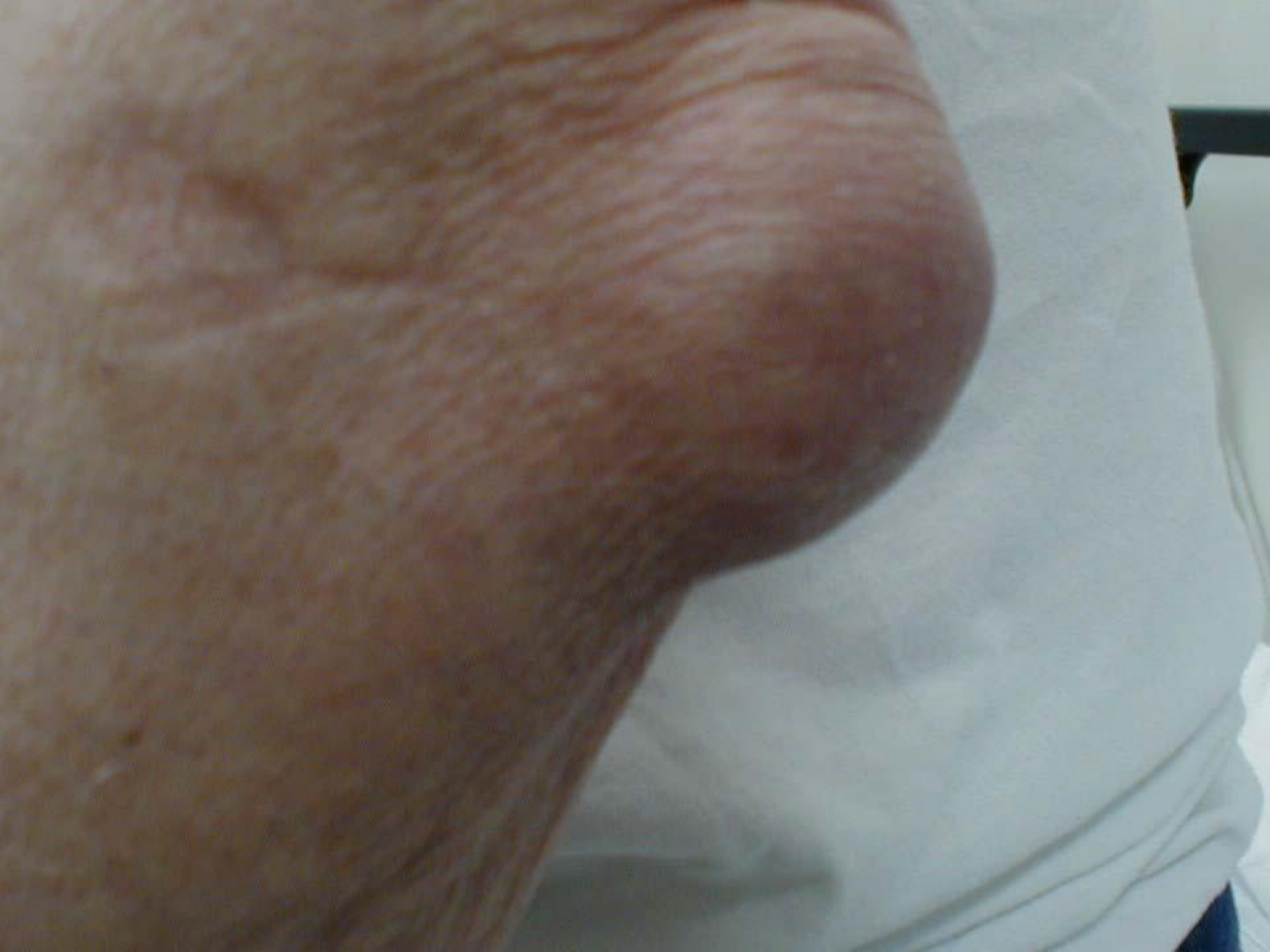- Nails
- Palms, Hands..... Grip strength and “knuckle sign” are very helpful.
- Do a Tinel’s sign while you are there
- Arms- slide hand along ulna for nodules

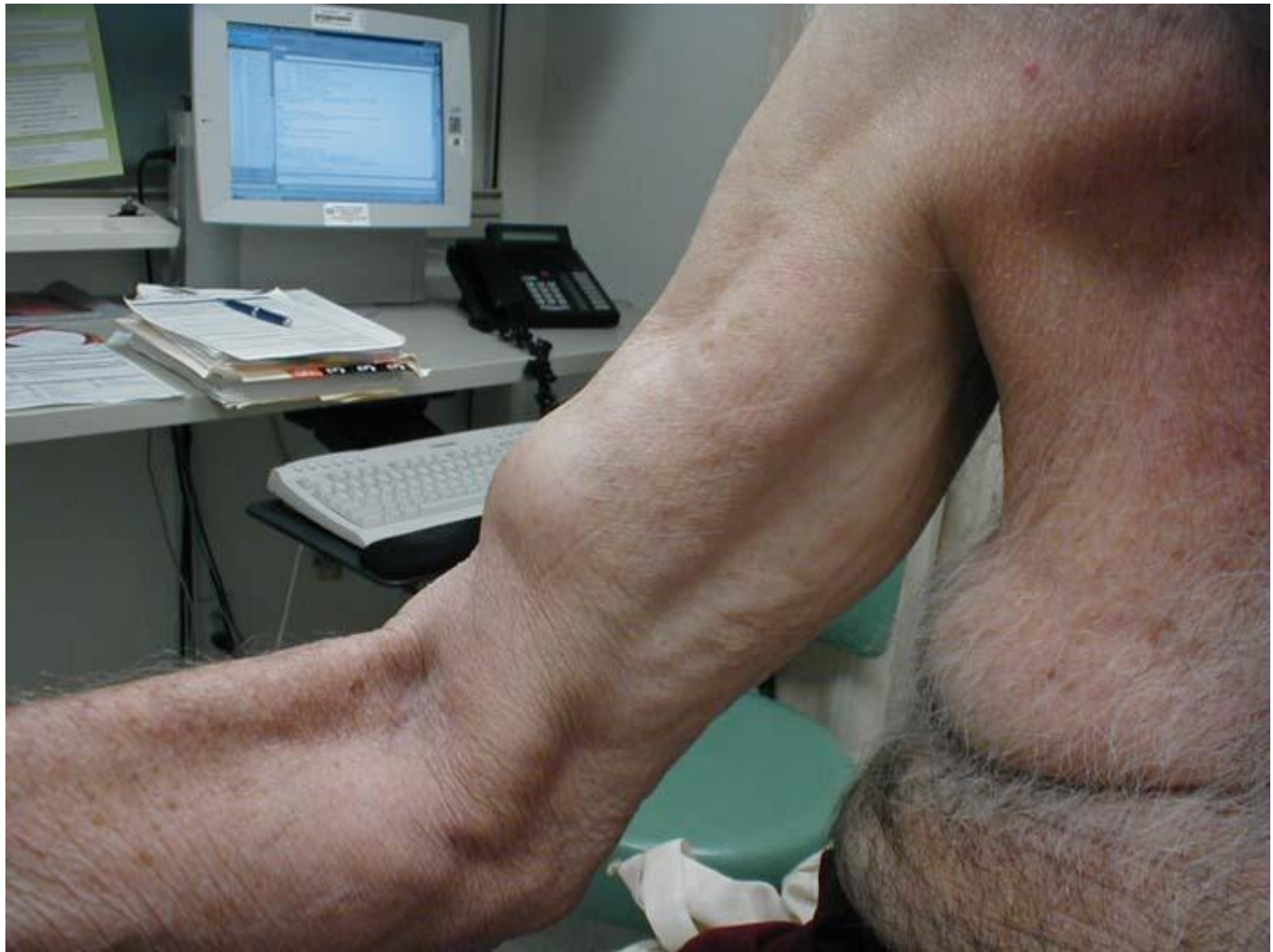What is this?



UPPER BODY

- Nails
- Palms, Hands..... Grip strength and “knuckle sign” are very helpful.
- Do a Tinel’s sign while you are there
- Arms- slide hand along ulna for nodules
- Elbow-synovial thickening at ulnar groove and epitroclear nodes are the “S4s” of the rheumatology consult!
- Olecranon bursal effusions are likely when elbow has full ROM





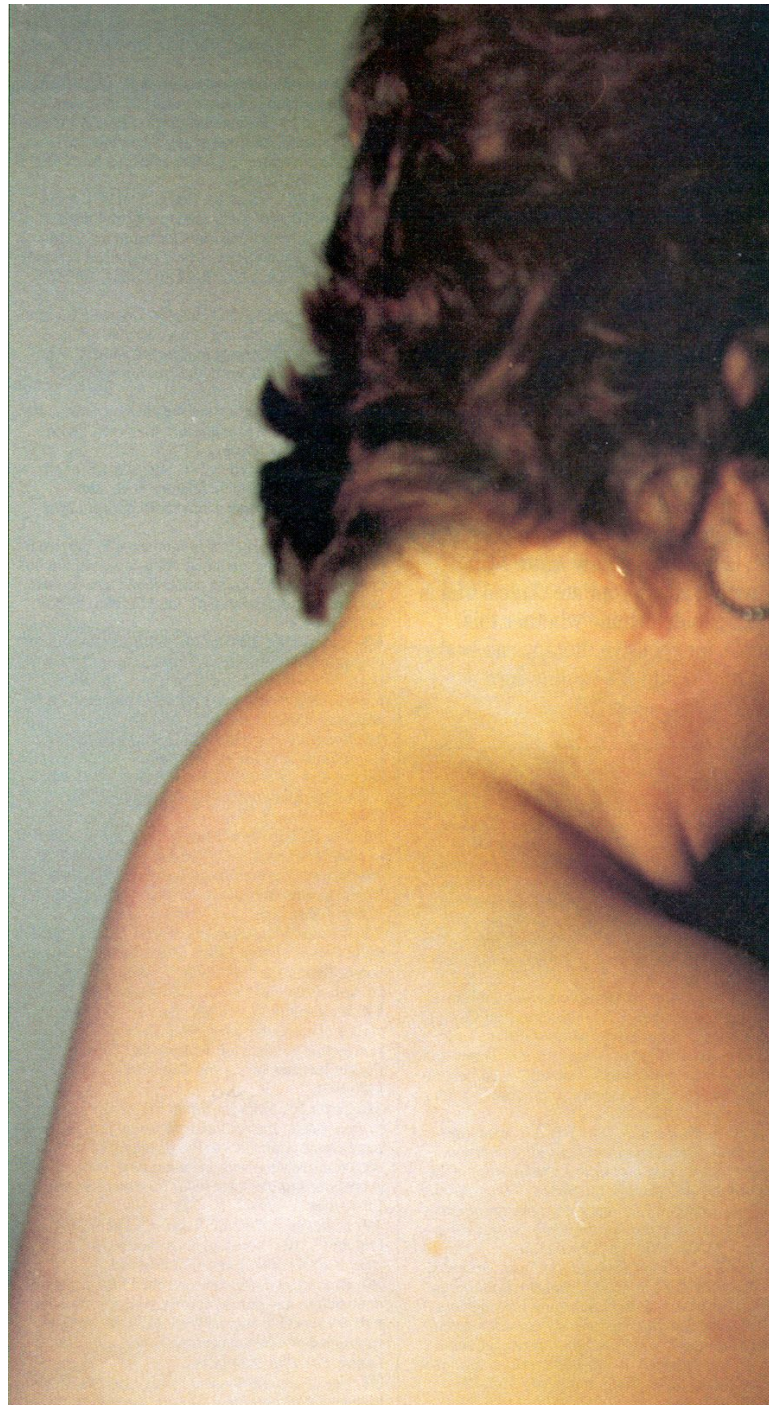UPPER BODY

- Cervical Spine anddon't forget the TMJ!
- Shoulders

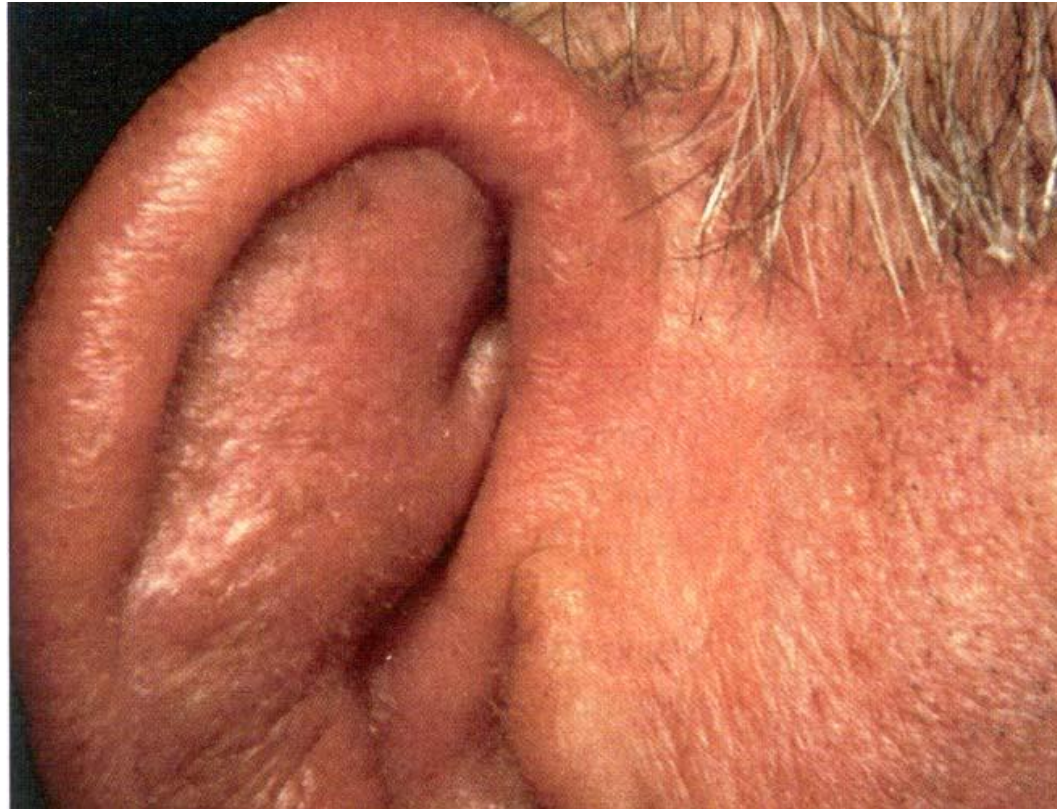Quick Assessment of Shoulder Function

- If the pt can abduct, elevate the arm above the head and touch the contralateral shoulder-then re-elevate and by reverse motion to touch the L-S spine..it is highly unlikely there is significant pathology present.
- Rotator Cuff assessment: by history there will be inability/pain on abducting arm $>90^\circ$ and by PX pain on internal /external rotation at 90°
- Pt may also have + beer can sign
- If there is abnormal and/or pain upon motion of the humerus in the A-P dimension, pathology is in the G-H joint

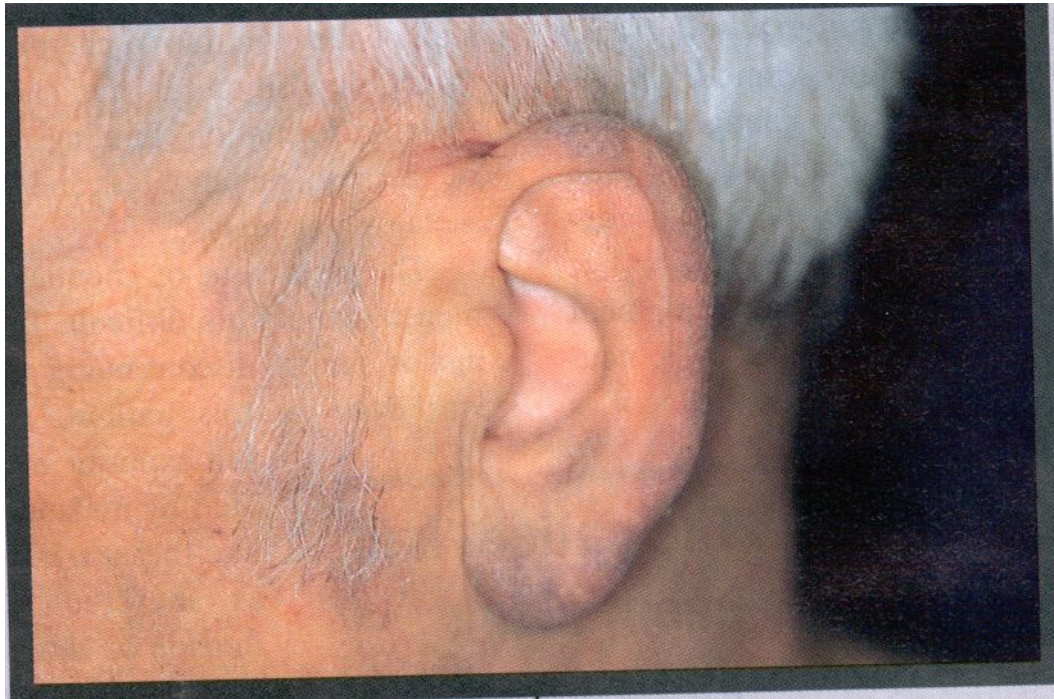
***WHAT MEDI-
CATION IS SHE
TAKING?***



A SLIGHTLY HIGHER YIELD
THAN SPINAL PERCUSSION



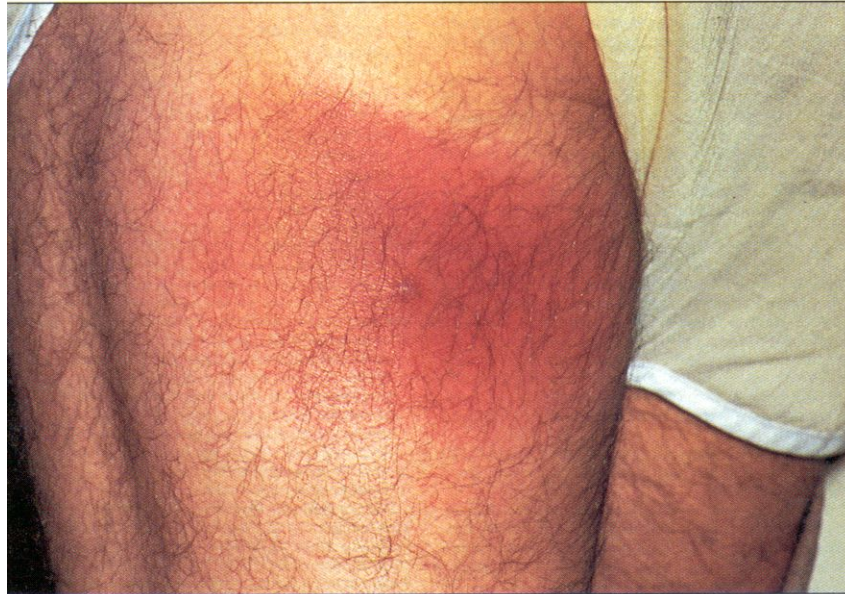DOES THIS MAN HAVE HEART
DISEASE?



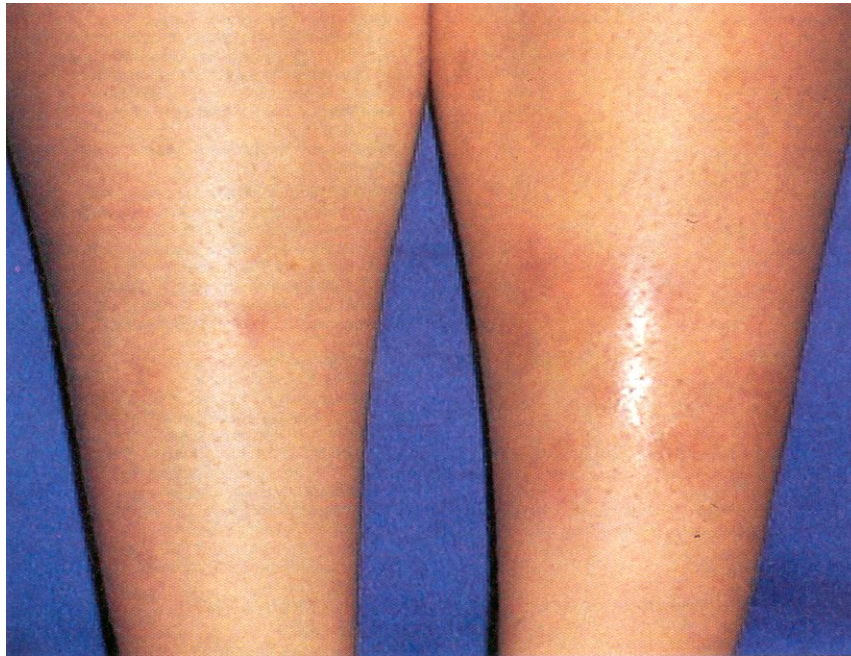LOWER BODY

- Skin

ERYTHEMA MIGRANS



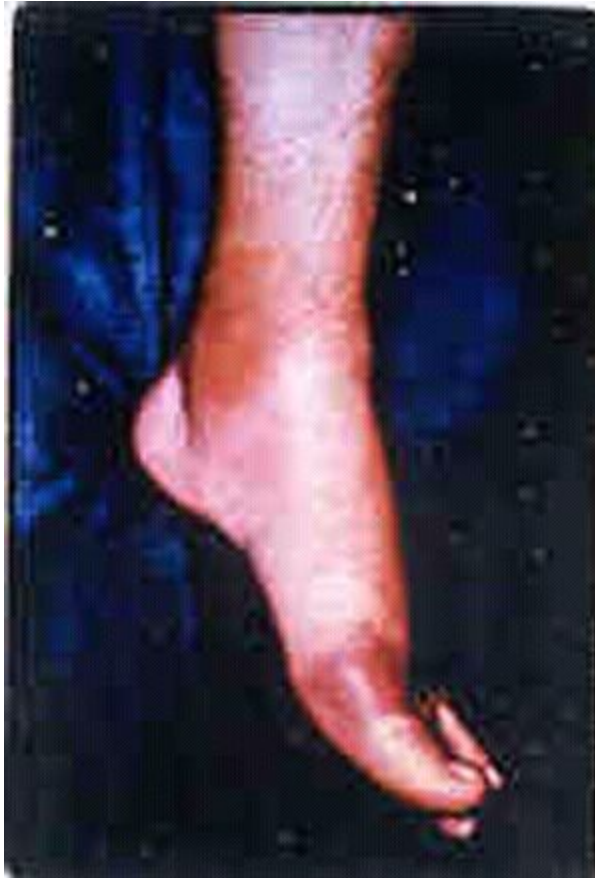ERYTHEMA NODOSUM



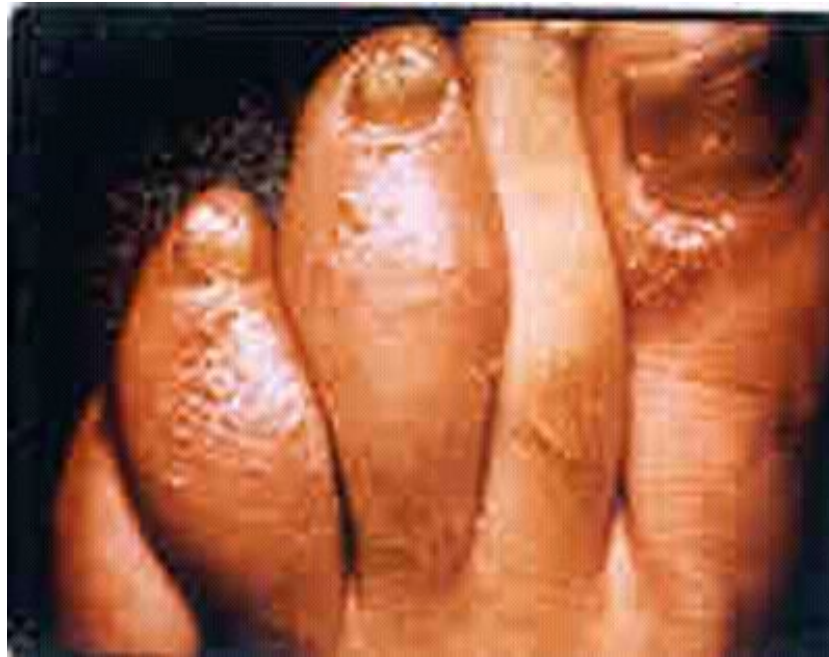LOWER BODY

- Skin
- Feet- MTPs are sentinel joints for inflammatory arthritis
- Ankle

Podagra



Psoriasis



LOWER BODY

- Knee
 - flexion
 - extension
 - patello/femoral clicking
 - don't forget the anserine bursa

WHAT IS THE ANSERINE BURSA?

- VERY COMMONLY MISSED SOURCE OF “KNEE” PAIN
- Worst at night and on stairs
- Obese
- DJD of knee common
- Know the muscles insertions that define it.
- Very easy to treat

LOWER BODY

- Skin
- Feet
- Ankle
- Knee
- Hip
 - internal/external ROM while knee flexed

TERMS/SYNDROMES

Arthralgia/arthritis

Myalgia

Baker's cyst

Ganglion cyst

Medial and lateral epicondylitis

Patello-femoral syndrome

Hypermobility syndrome

The End

Recording the Exam

- S...L...T graded on a scale of 1-4
- Writing that a joint has fluid and is warm and tender means a lot
- ROM..”normal vs abnormal” can suffice in most circumstances
- Stickpeople can be helpful