

DME IN 2015: KEY DEVELOPMENTS IN PATIENT CARE

Moderator

Neil M. Bressler, MD

Professor of Ophthalmology;
Chief, Retina Division
The Wilmer Eye Institute
Johns Hopkins University School
of Medicine
Baltimore, USA

Panelist

Anat Loewenstein, MD, MHA

Chair, Department of Ophthalmology
Tel Aviv Medical Center;
Professor of Ophthalmology;
Incumbent, Sydney A. Fox Chair
in Ophthalmology
Tel Aviv University
Tel Aviv, Israel

Program Goals

- Review key new data released during 2015 on the use of anti-VEGF therapy for DME
- Discuss implications of these data for clinical practice and recommendations for managing patients with DME

Managing the Patient With No Clinical Signs and Symptoms of DME

Presentation

- Symptoms: none
- Clinical exam: normal
- Visual acuity: 20/20
- OCT: small cysts



Recommendation

- Treatment: none
- Plan: observe for signs of progression



Consider treatment if:

- Decreased visual acuity
- Increased retinal thickening
- Increased cysts

Managing the Patient With Mild Visual Impairment Due to CME

Presentation

- Clinical exam: retinal thickening, no proliferative retinopathy
- Visual acuity: 20/40

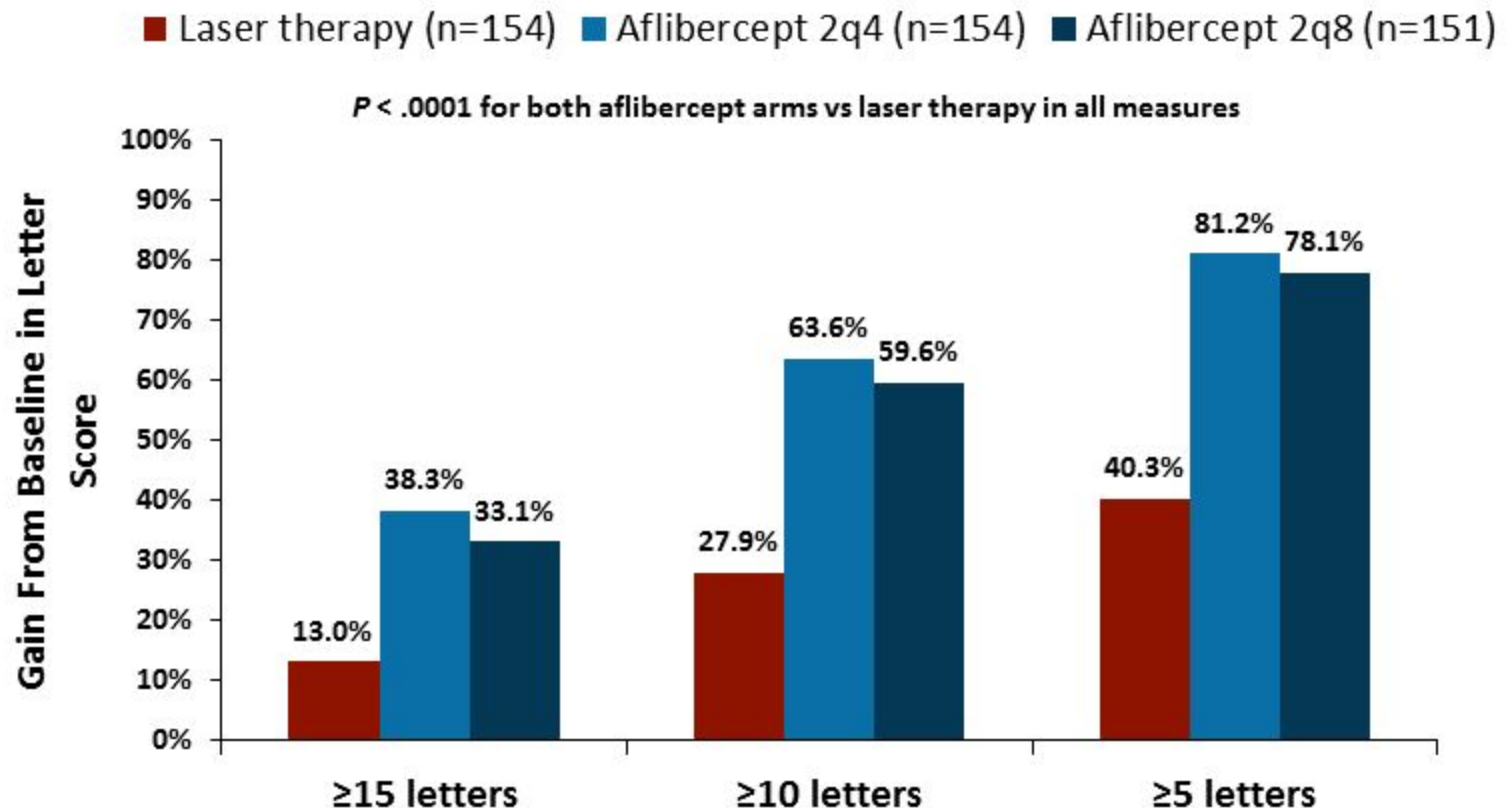


Recommendations

- Treatment: anti-VEGF agent
- Consider laser therapy during follow-up if necessary

Anti-VEGF vs Laser Therapy: Improvements in Visual Acuity

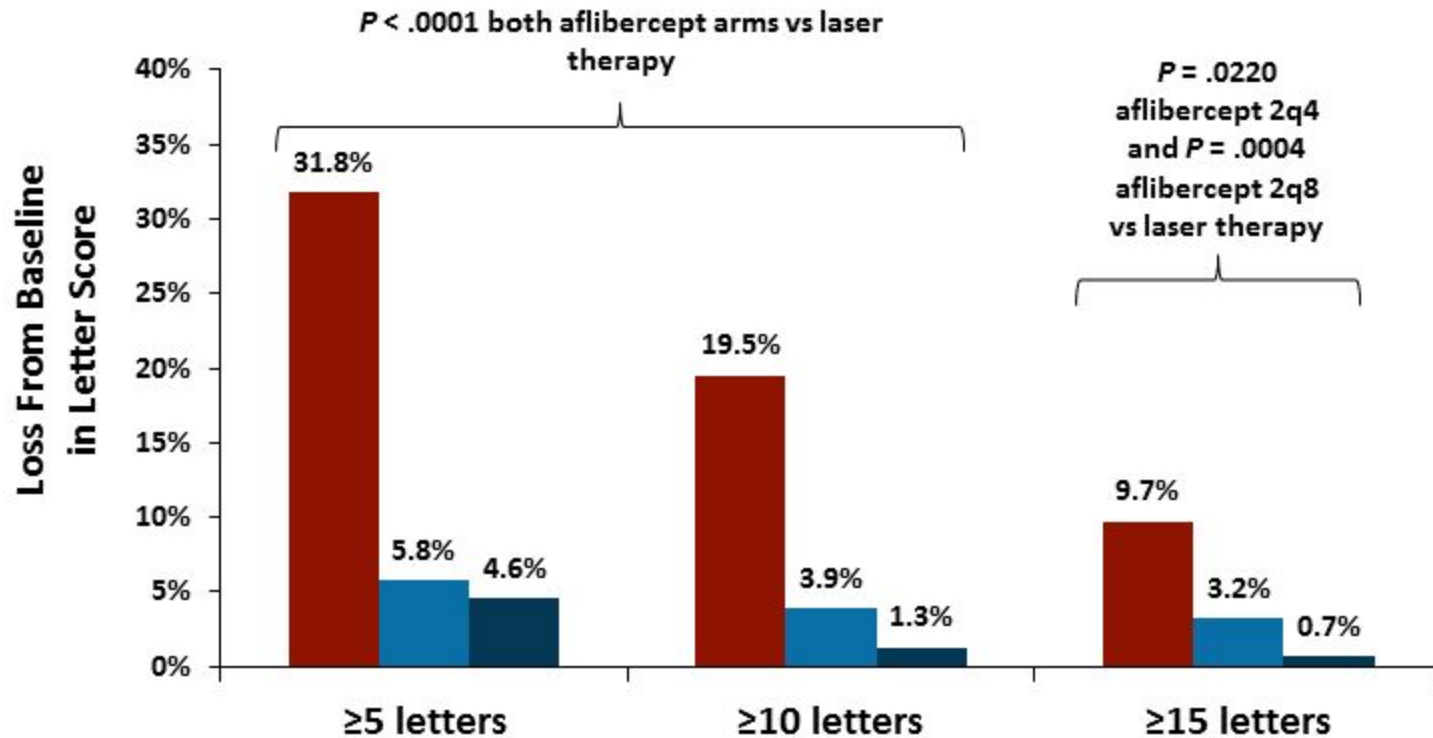
VISTA 100-Week Results



Anti-VEGF vs Laser Therapy: Declines in Visual Acuity

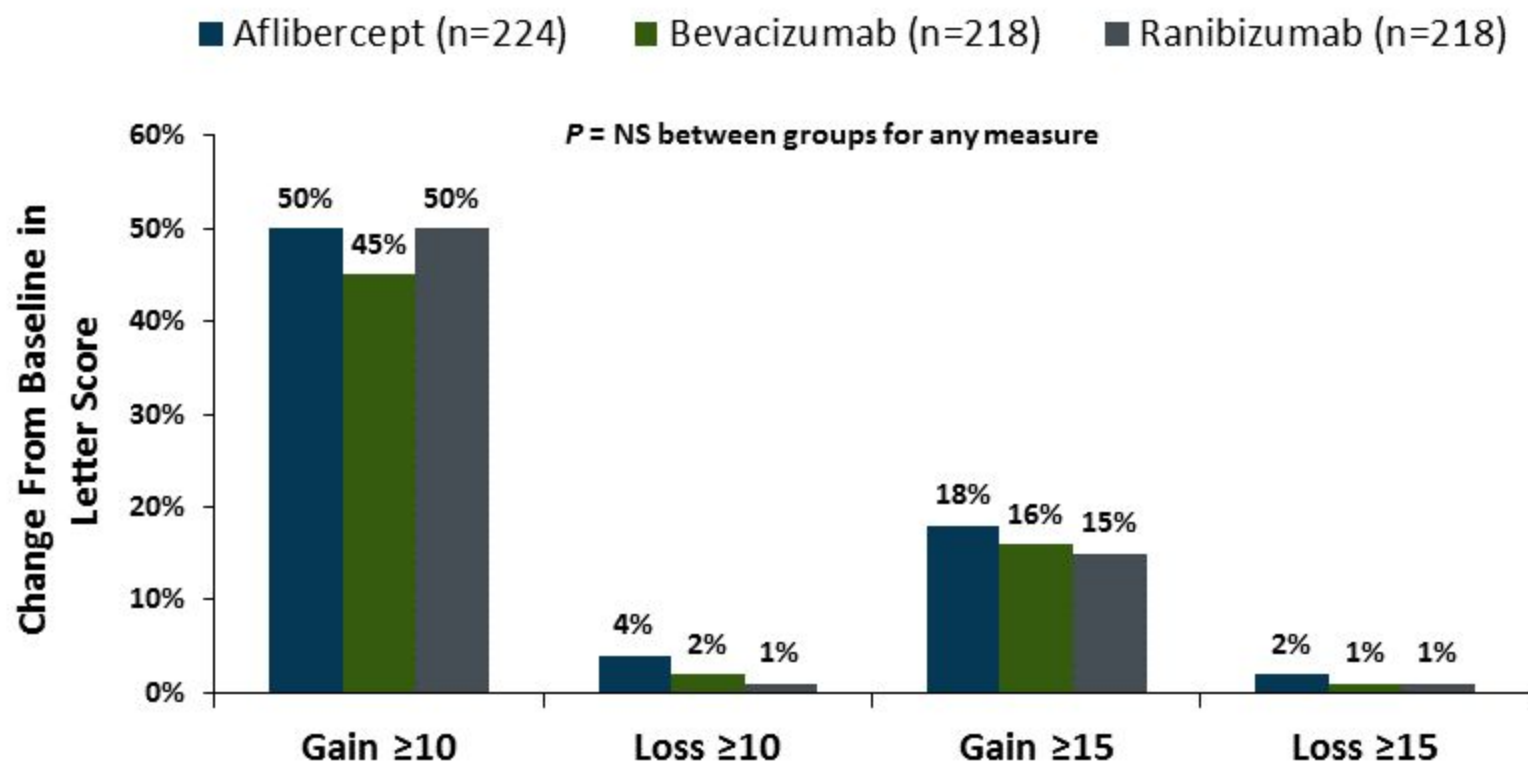
VISTA 100-Week Results

■ Laser therapy (n=154) ■ Afibercept 2q4 (n=154) ■ Afibercept 2q8 (n=151)



Selecting an Anti-VEGF Therapy for Mild Visual Impairment

Protocol T 52-Week Results



Patients with baseline visual acuity letter score 78-69, equivalent to approximately 20/32 to 20/40

Protocol T: Systemic Adverse Events

| APTC Events^[b] | Aflibercept (n=224) | Bevacizumab (n=218) | Ranibizumab (n=218) |
|----------------------------------|--------------------------------|--------------------------------|--------------------------------|
| Nonfatal MI | 2% | <1% | 1% |
| Nonfatal stroke | 0 | 2% | 2% |
| Vascular death | <1% | 2% | 1% |
| Any APTC event | 3% | 4% | 5% |

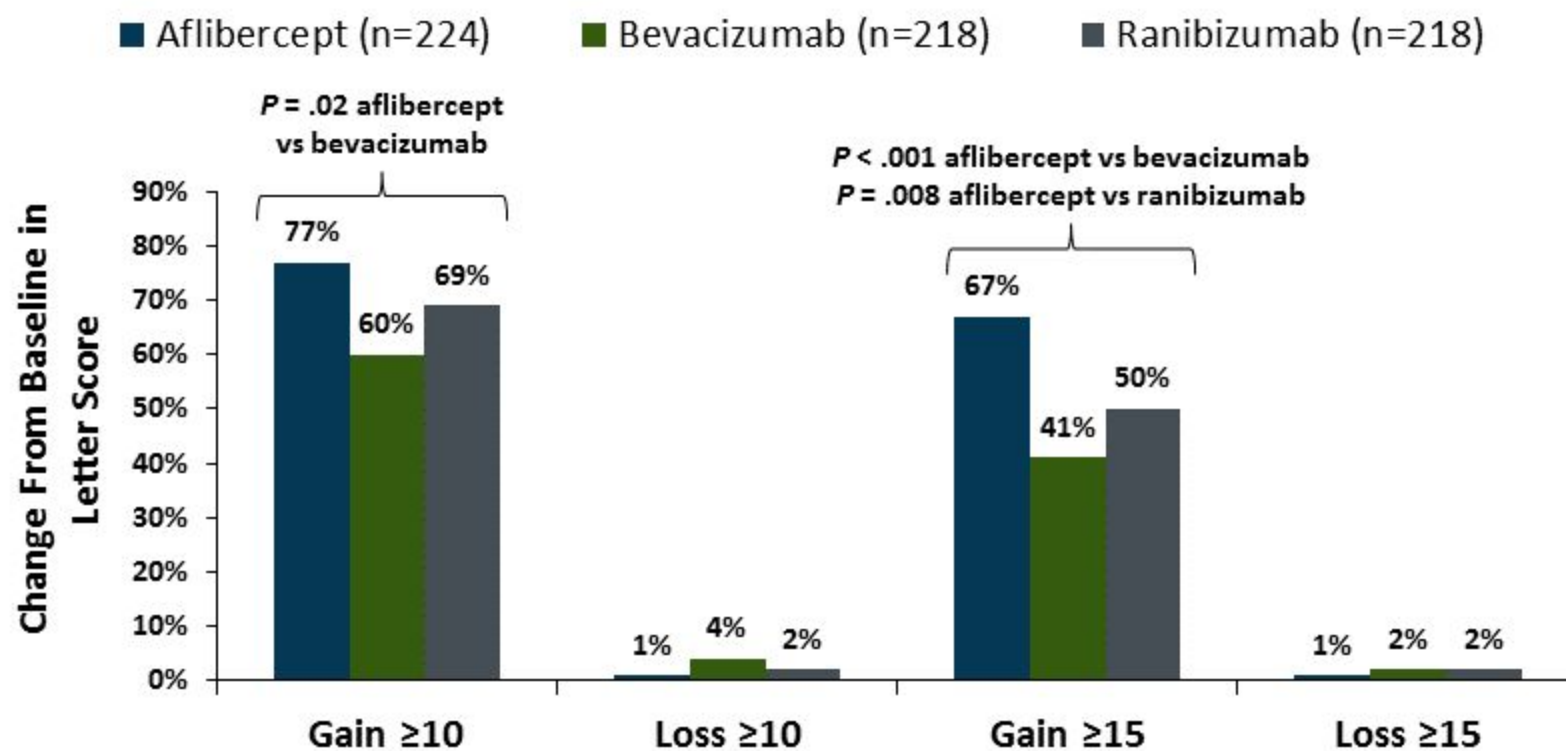
| Prespecified Events^[a] | | | |
|--|-----|-----|-----|
| Death (any cause) | 1% | 2% | 2% |
| Hospitalization | 21% | 18% | 22% |
| SAEs | 26% | 21% | 25% |
| Gastrointestinal | 20% | 18% | 17% |
| Kidney events | 13% | 11% | 11% |
| Hypertension events | 12% | 7% | 12% |

a. Diabetic Retinopathy Clinical Research Network. *N Engl J Med*. 2015;372:1193-1203.

b. Antiplatelet Trialists' Collaboration. *BMJ*. 1994;308:81-106.

Selecting an Anti-VEGF Therapy for Moderate Visual Impairment

Protocol T 52-Week Results



Patients with baseline visual acuity letter score <69, equivalent to approximately 20/50 or worse

Managing the Patient With Mild or Moderate Visual Impairment Due to DME

Treatment

- 3 injections of anti-VEGF therapy



Outcomes

- OCT: normal
- Visual acuity: 20/20

Next steps:

- Withhold injections
- Monitor monthly
- Resume if/when retina thickens



Managing the Patient With Minimal Improvement After Anti-VEGF Therapy

Treatment

- 5 injections of anti-VEGF therapy



Outcomes

- OCT: improved, but not normal
- Visual acuity: improved but not 20/20

Next steps:

- Continue injections for as long as improvement continues
- Target maximum improvement, not number of injections



Defining Response to Anti-VEGF Therapy: DRCR Algorithm

Improvement

- **OCT:** > 10% decrease in central subfield thickness
- **Visual acuity:** ≥ 5 letter gain (unless 20/20 or better)

No further improvement

- **OCT:** < 10% decrease in central subfield thickness
- **Visual acuity:** < 5 letter gain since the most recent injection; unlikely that additional treatment would provide further benefit

Success

- **OCT:** central subfield thickness < 250 μm
- **Visual acuity:** 20/20 or better

Failure

- Worsening despite treatment
- Serious side effects associated with treatment precluding additional treatment

Managing the Patient With No Improvement After Anti-VEGF Therapy

Treatment

- 6 injections of anti-VEGF therapy



Outcomes

- OCT: not normal
- Visual acuity: not improved

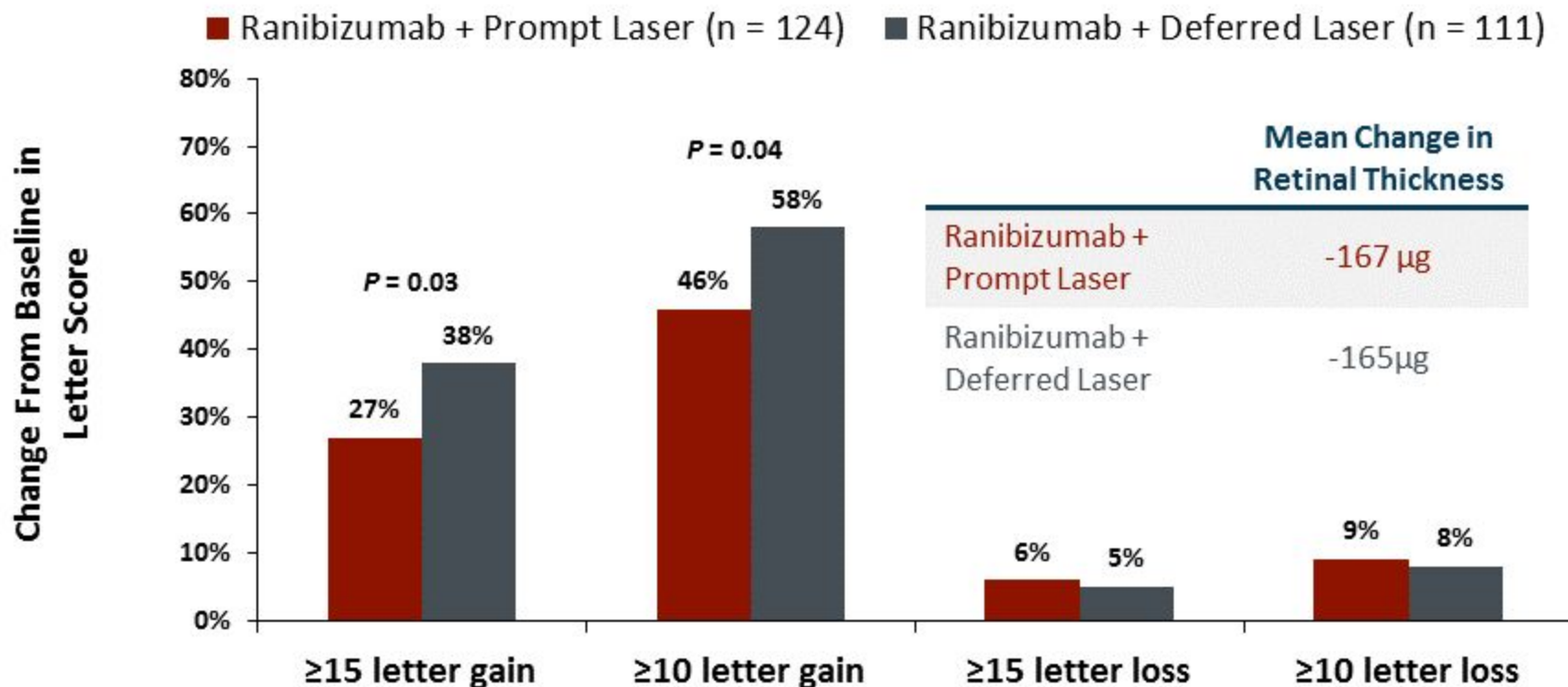
Next steps:

- Consider adding focal/grid laser
- Target thickened areas, micro-aneurysms



Delayed Use of Focal/Grid Laser Therapy After Anti-VEGF Therapy

Protocol I 5-Year Results



Prompt laser therapy given 7-10 days after initial ranibizumab injection. Deferred laser therapy delayed for at least 24 weeks, and only given if the eye was not improving from injection alone and there was clinically significant macular edema

Managing the Patient With No Improvement After Anti-VEGF Therapy and Laser Therapy

Treatment

- 6 injections of anti-VEGF therapy
- Focal laser therapy



Outcomes

- OCT: not normal
- Visual acuity: not improved, but nor worsening
- ***Pseudophakic***



Next steps:

- Consider use of corticosteroids for persistent edema

Managing the Patient With No Improvement After Anti-VEGF Therapy and Laser Therapy (cont)

Treatment

- 6 injections of anti-VEGF therapy
- Focal laser therapy



Outcomes

- OCT: not normal
- Visual acuity: not improved, but nor worsening
- *Phakic*



Next steps:

- Consider corticosteroids cautiously because of risk for cataract and permanent vision loss with worsening edema

PRP vs Anti-VEGF Therapy for Proliferative Diabetic Retinopathy and DME

Protocol S 2-Year Results

| Visual Acuity | Ranibizumab (n=160) | PRP (n=168) | P value |
|---------------------------------------|------------------------|----------------|---------|
| Letter score at 2 years, mean | 78.7 | 76.2 | |
| Change from baseline to 2 years, mean | 2.8 | 0.2 | .11 |
| AUC, mean | 4.5 | -0.3 | < .001 |

| Central Subfield Thickness | Ranibizumab (n=149) | PRP (n=161) | P value |
|---------------------------------------|------------------------|-------------------|---------|
| At 2 years, mean | 210 μm | 243 μm | |
| Change from baseline to 2 years, mean | -47 μm | -3 μm | < .001 |


| Changes in Diabetic Retinopathy | Ranibizumab (n=191) | PRP (n=203) | P value |
|---------------------------------|------------------------|----------------|---------|
| Retinal detachment | 6% | 10% | .08 |
| Vitreous hemorrhage | 27% | 34% | .09 |
| Vitrectomy | 4% | 15% | < .001 |

Managing the Patient With Proliferative Diabetic Retinopathy and DME

Treatment

- 6 injections of anti-VEGF therapy


Edema
Improving



- Continue anti-VEGF therapy

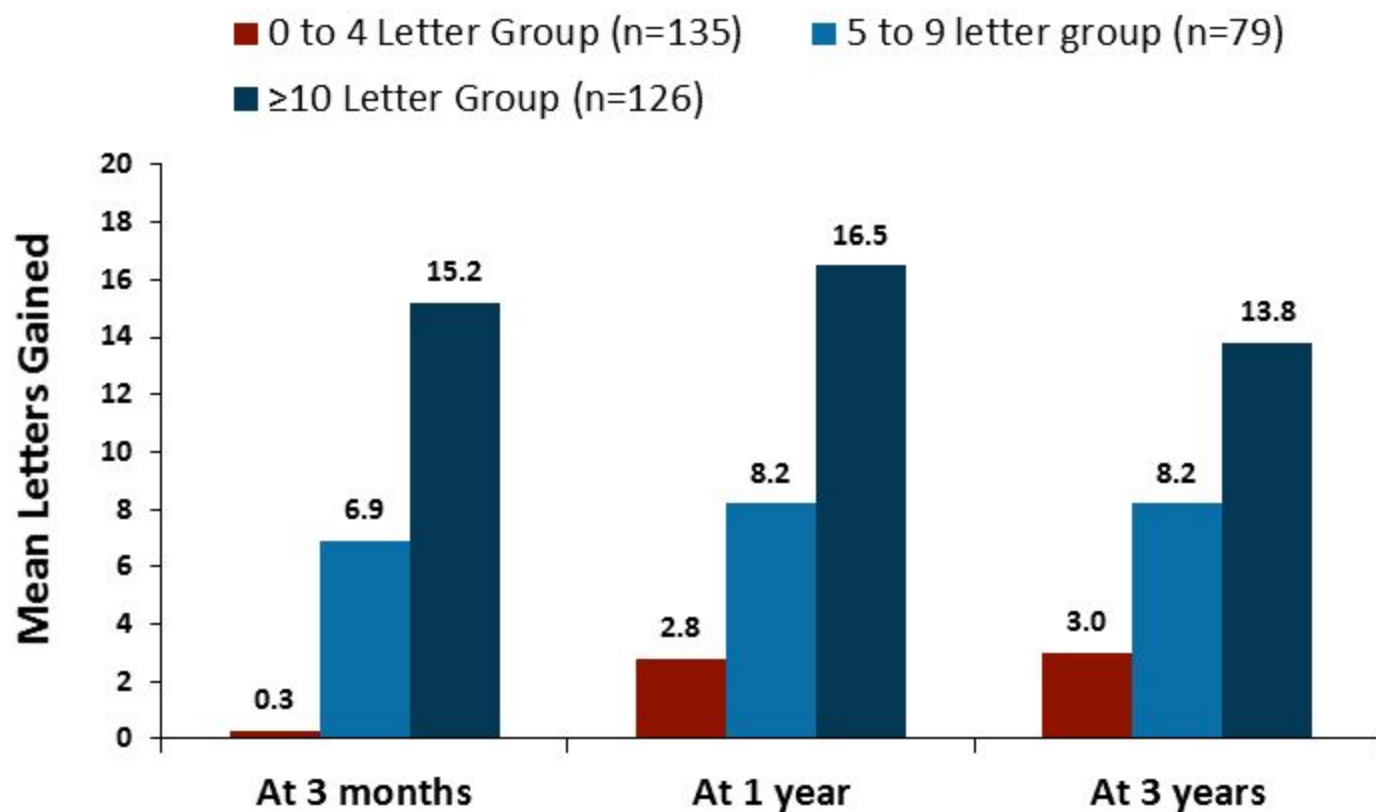
Edema Resolved
Proliferation Stable

- Observe regularly
- Resume anti-VEGF therapy with evidence of proliferation or edema



Predicting Response to Anti-VEGF Therapy

Post Hoc Analysis of Protocol I



Conclusions

- Data presented and published in 2015 offer new insight into optimal use of anti-VEGF therapy in DME
- New evidence for improved selection of anti-VEGF therapy for patients with mild and moderate visual impairment
- New guidance on the number of anti-VEGF therapy injections needed to see improvement and how to address nonresponding cases
- New approaches for patients with proliferative diabetic retinopathy

Abbreviations

APTC = Antiplatelet Trialists' Collaboration

AAO= American Academy of Ophthalmology

DME = diabetic macular edema

DRCR = Diabetic Retinopathy Clinical Research Network

MI = myocardial infarction

OCT = optical coherence tomography

PRP = panretinal photocoagulation

SAE = serious adverse event

VEGF = vascular endothelial growth factor