

Narrow pelvis in obstetrics.  
Malposition.

**PATELIYA BHARGAV**  
**GROUP NO.163 B**

# ANATOMIC narrow pelvis

- This reduction in one or more dimensions of the pelvis 1 cm or more

Classification shape narrowing :  
(common form)

- 1. Obscheravnomernosuzhenny pelvis
- 2. Ploskie basins:
  - Simple flat
  - Obschesuzhenny flat
  - Ploskorahitichesky
- 3. Poperechnosuzhenny

# Rare forms of female pelvis

- Kososmeschenny kososuzhenny and pelvis  
infantile pelvis  
Osteomalalyatichesky pelvis  
Android or funnel  
kyphotic

# Classification according to the degree of narrowing of the pelvis (By Malinowski, MS)

By true conjugate

1 degree - 10 - 8cm

Grade 2 - 8 - 6cm

Grade 3 - 6 cm and below (absolutely  
narrow pelvis)

# REASONS

- Violations of fetal development girl  
violation of mineral metabolism  
Infantilism Rickets Severe diseases of the  
internal organs  
Bone tuberculosis, polio  
Early heavy child labor  
Young nulliparous (13 - 19yo)  
Wearing tight pants ("denim pelvis")

- Diseases of the bone (osteomalacia, etc.).  
osteomyelitis, bone tuberculosis.
  - . Injury (lesion of the hip - shortening -  
obliquely combined pelvis).

# NARROW DIMENSIONS pelvic

- By narrowing the shape of the pelvis

D.Spinarum D.cristarum D. trochanterica C. externa C.diagonalis C.vera

D.Spinarum D.cristarum D. trochanterica C. externa C.diagonalis C.vera

Normal 25 28 31 20 13 11

pelvis.

Obscheravno- 24 26 29 18 11 9

mernosuzhen-

ny.

Prostoy- 25 28 31 18 11 9

flat.

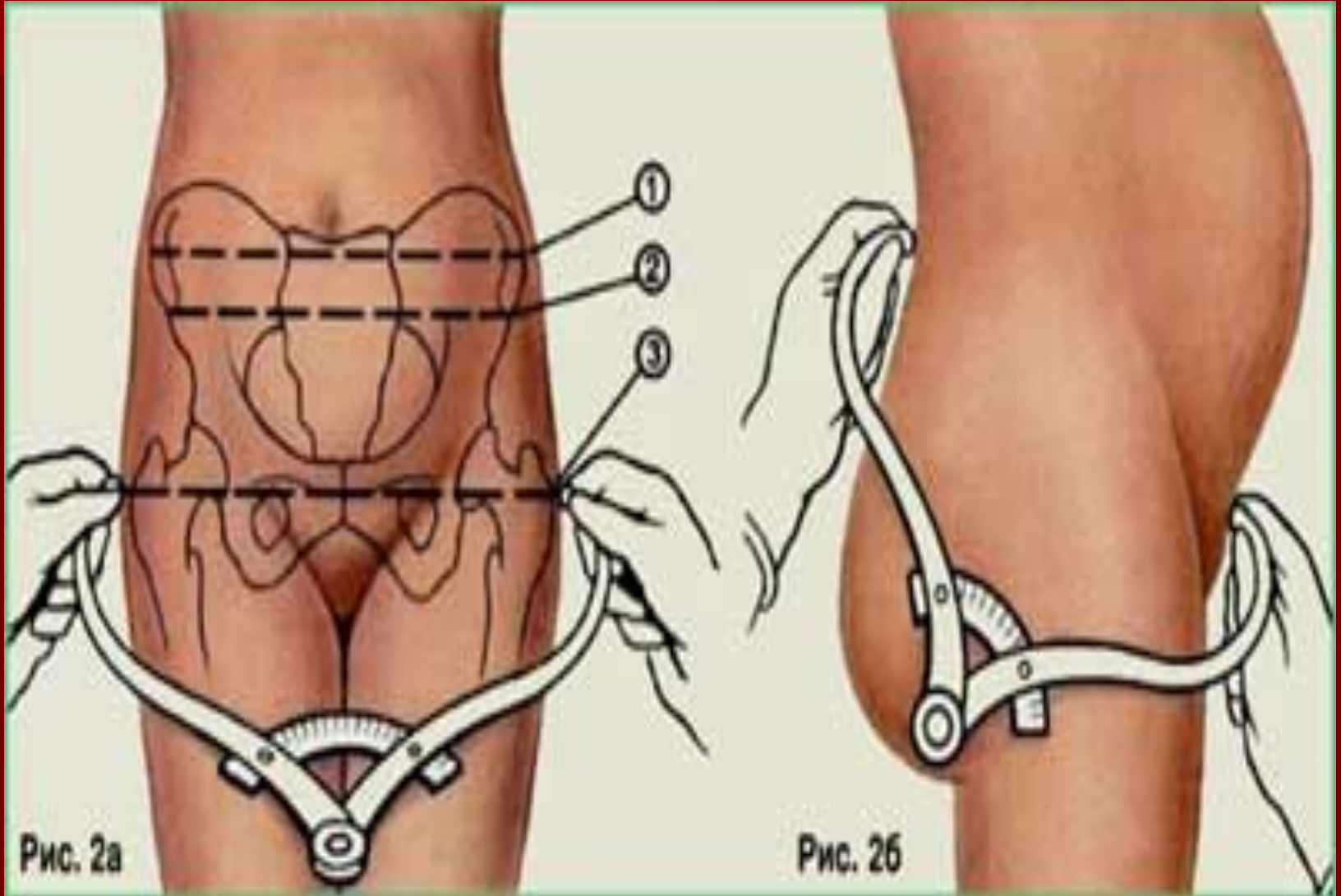
Ploskora-

Hitichesky 27 27 31 17 10 8

transversely

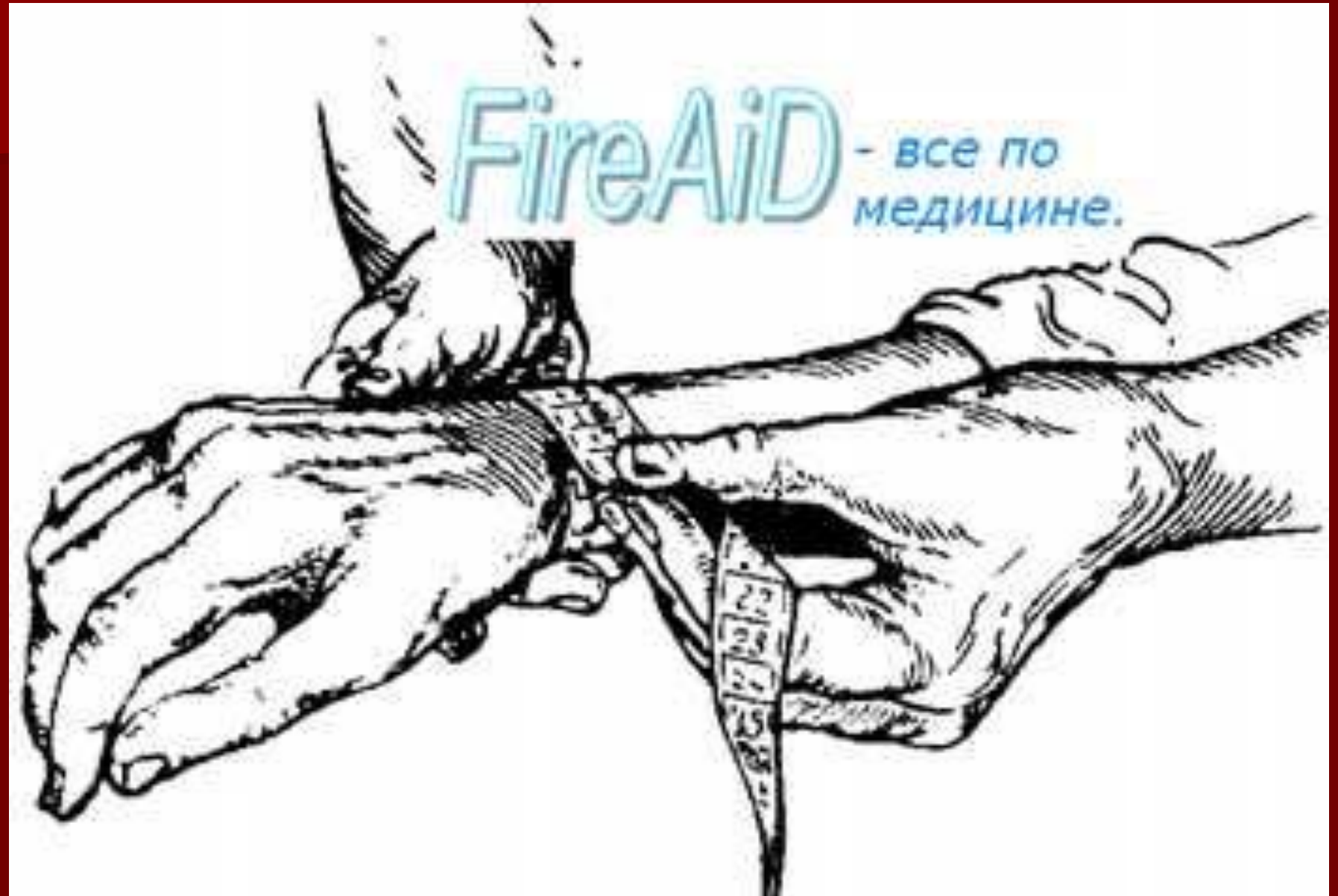necked 25 25 30 20 13 11

# Pelviometriya





# index Solovyov



# Simple flat pelvis

1. All direct size is reduced, due to the fact that the sacrum is uniformly close to the pubic articulation.
2. The iliac wings are widely deployed.
3. Sacral flattened diamond that is less than 11 cm in the vertical.

# Ploskorahitichesky pelvis

The sacrum can be described as

"There are four" (ears) :

· Flattened · Shortened

Broadened · · Thinned

# Ploskorahitichesky pelvis

- Significant expression of expansion of the ilium.

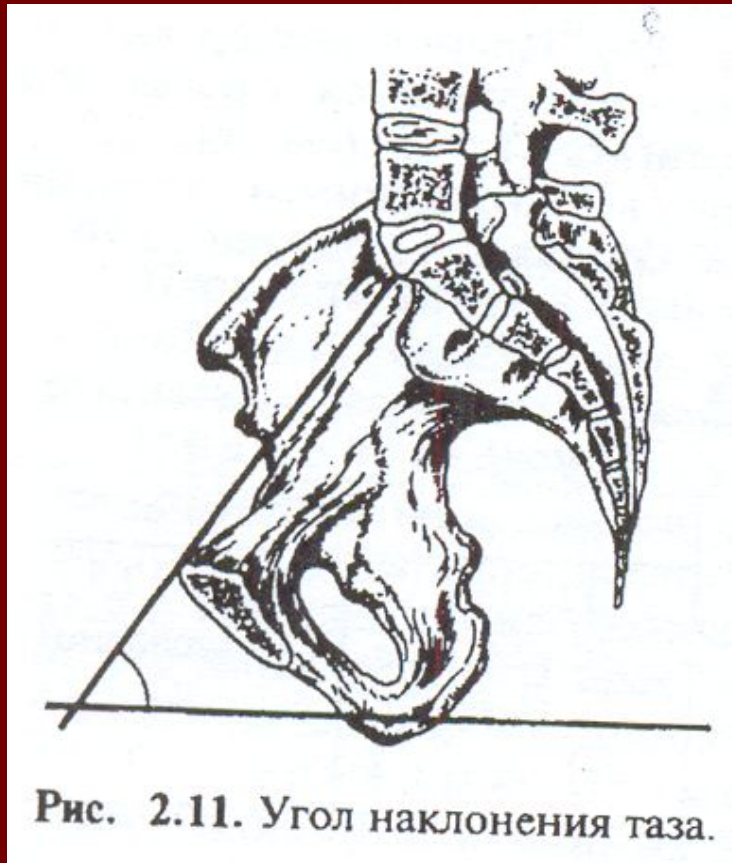
Distancia spinarum = distancia cristarum  
unlike simple flat pelvis.

Pubic angle large

# Poperechnosuzhenny pelvis :

1. An elongated diamond sacral
2. Reduction of the transverse dimensions
3. Cool standing iliac wing (or low detailed).
4. Narrow pubic arch

# The angle of inclination of the pelvis.



# Clinical signs of growth - below 150 cm or above 180 cm AGE-less than 20 years

Pointed or pendulous abdomen

breech

Lateral position of the fetus

CHANGE Michaelis rhombus

CHANGING size of the pelvis  
index Solovyov

Различные формы сужений таза.

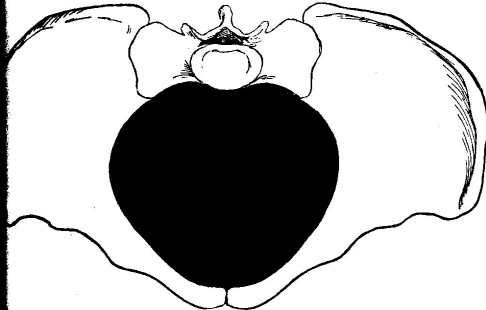


Рис. 401. Нормальный тазъ.

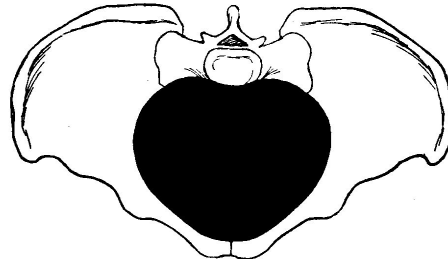


Рис. 402. Равноѣрно-общесуженный тазъ.

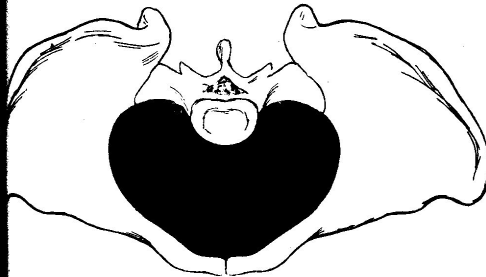


Рис. 403. Плоскій тазъ.

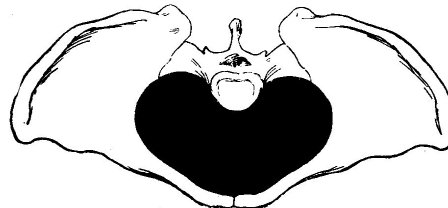


Рис. 404. Обще-суженный плоскій тазъ.

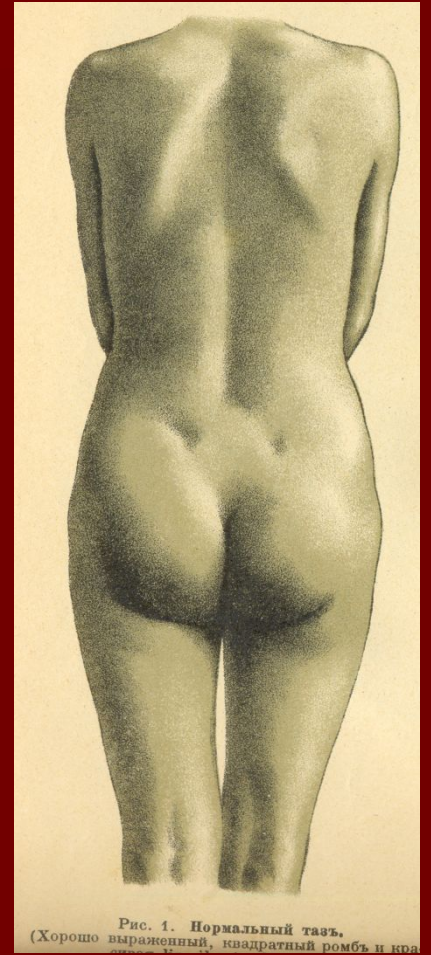
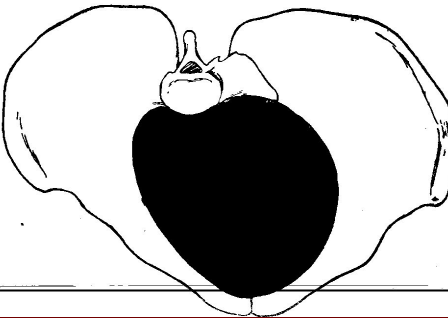
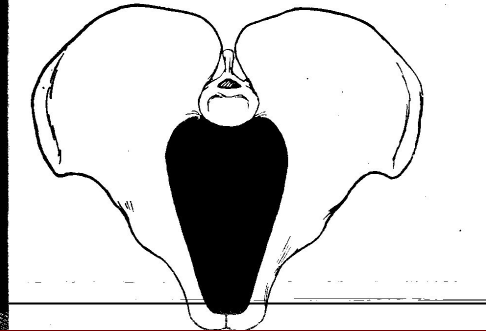


Рис. 1. Нормальный тазъ.  
(Хорошо выраженный, квадратный ромбъ и кра...



# Diamond shaped Michaelis at anatomically narrow pelvis

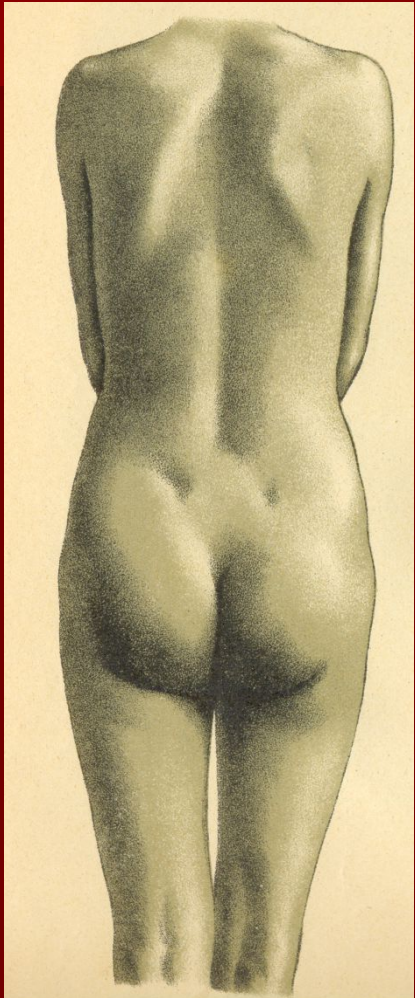


Рис. 1. Нормальный таз.  
(Хорошо выраженный, квадратный ромб и кра...

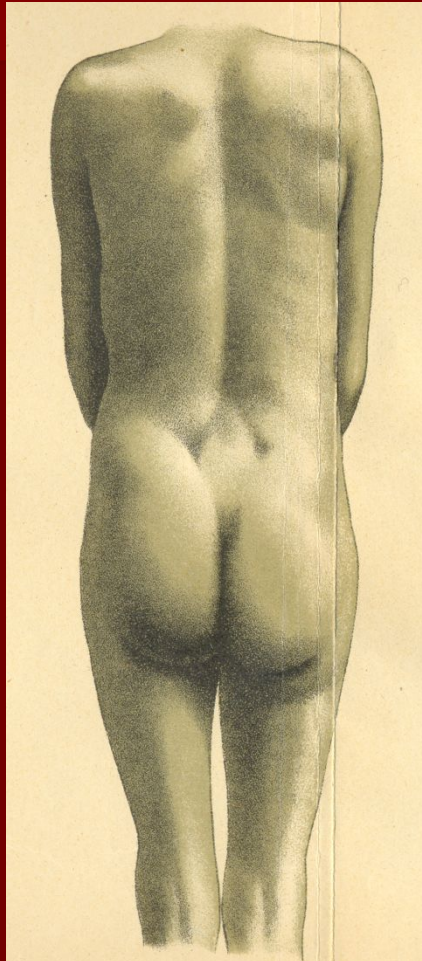
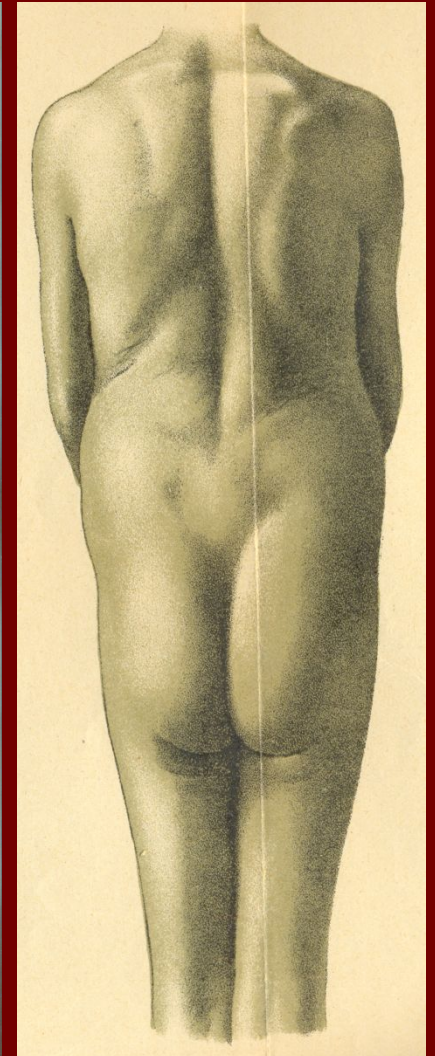
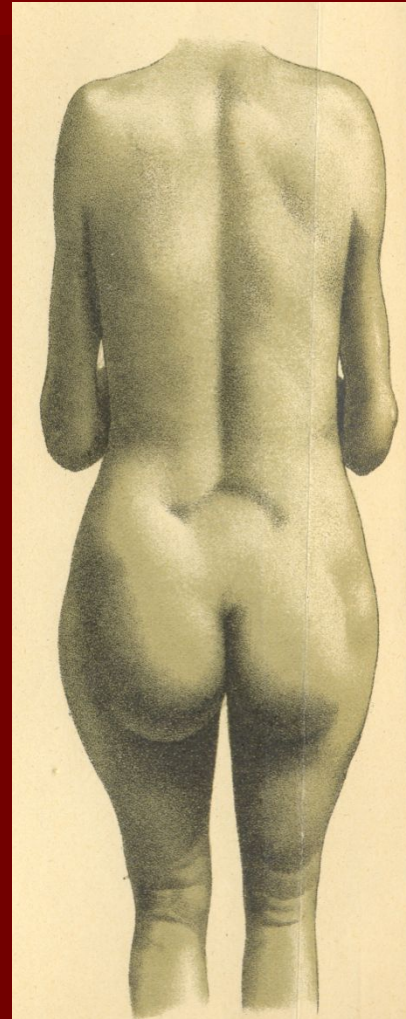
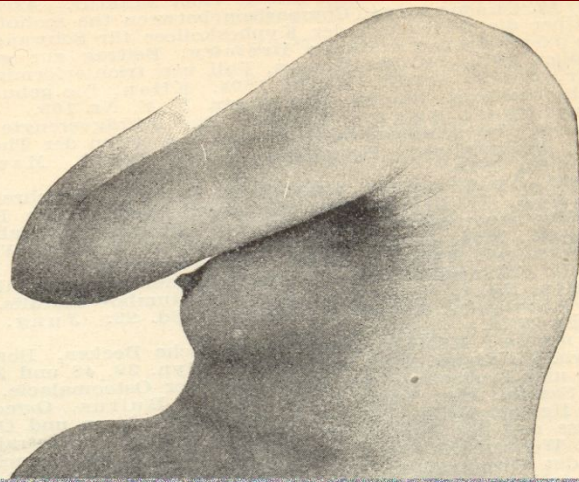
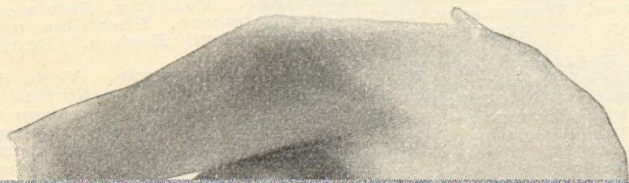

Рис. 2. Обще-равномерно-суженный таз.  
(Ромб узок, незначительная distantia ileo-trochanterica.)



ысоко подвижной, плоду, а  
олость. Необходимое для плода про-  
тво создается путем болѣе сильнаго  
кенія брюшныхъ стѣнокъ кпереди. У  
нъ невысокаго роста, гдѣ брюшная  
ь низкаго размѣра, а между тазомъ и  
ной дугой и безъ того не много мѣста,  
ьно рано и даже при первой беремен-  
образуется отвислый животъ. У  
болѣе высокаго роста образуется, если



# Complications of labor with a narrow pelvis

## FIRST PERIOD

- Prenatal and early rupture of water  
Chorioamnionitis and infection of the fetus, uterus  
Uterine inertia  
Vypavdenie loop cord, small parts of the fetus  
prolonged labor  
asphyxia

# Complications of labor with a narrow pelvis

## SECOND PERIOD

Prolonged standing Head in one plane  
uterine rupture

Stretching and rupture of the symphysis pubis

## Third and early postpartum

Genitourinary fistulas and rectal

Bleeding in 3 and the early postpartum period  
perinatal mortality

maternal mortality

# Complications of labor with a narrow pelvis

# Delivery in OUT

- With 1-degree of narrowing of the pelvis - 90% of births end vaginally
  - 10% - operational by
- When the 2-degree of narrowing - 70% of births by surgery, 30% - vaginally
- When the 3-degree of narrowing - 100% surgically

Clinically narrow pelvis:  
Size mismatch pelvic size of the  
fetal head

Reasons:

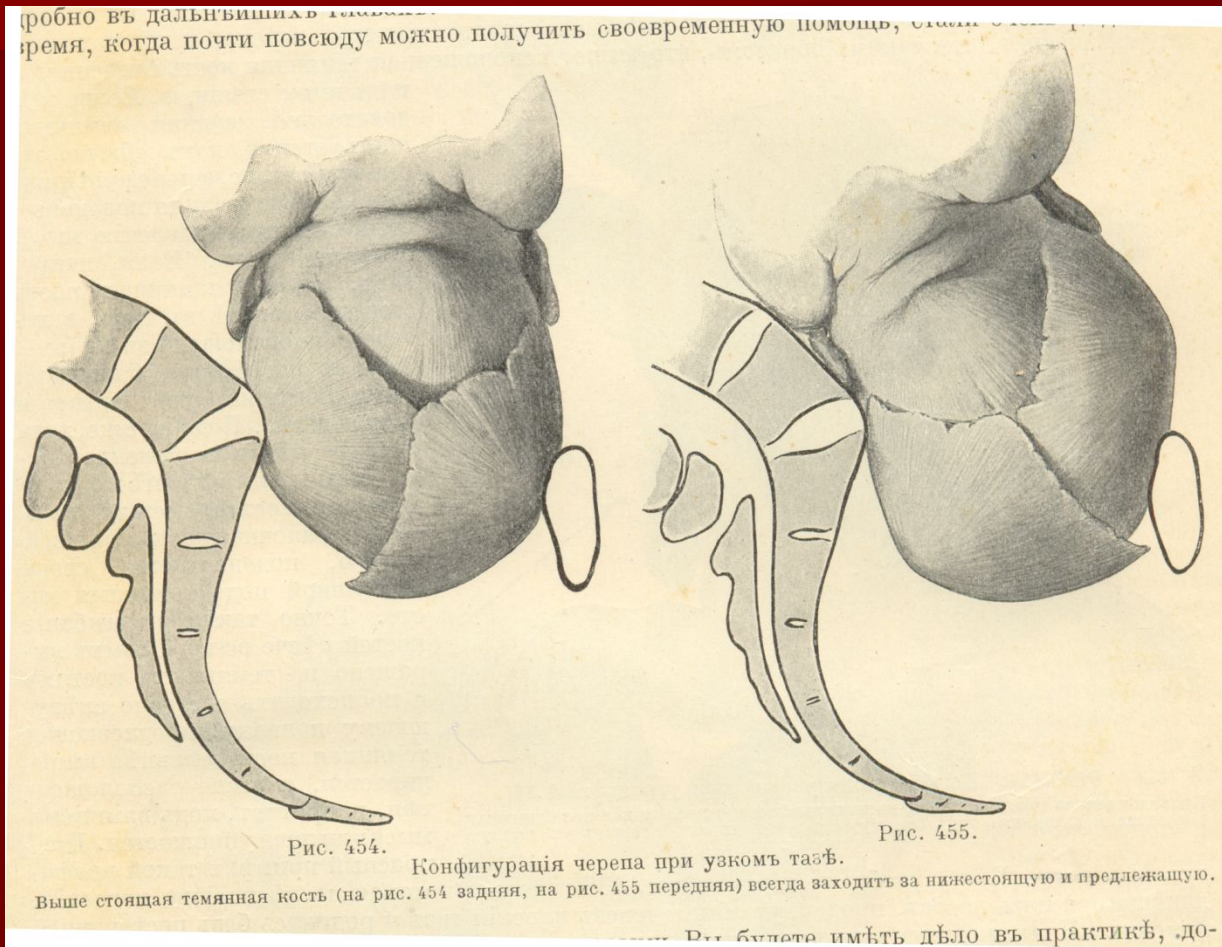
- Large fetus,  
anatomically narrow pelvis,  
Incorrect insertion of the head,  
running transverse position of the  
fetus,  
hydrocephalus

# Prolonged labor. Causes clinically narrow pelvis:

- The combination of small and large degree of narrowing of the fetus - 60%.
- Abnormal insertion and presentation of the head - and extensor asinkliticheskie at small narrowing in the normal pelvis - 34%.
- The large size of the head and a normal pelvis - 10%
- Organic changes of the pelvis - 6%.



# mismatch HEAD size of the pelvis during childbirth



diagnostics:

The diagnosis of clinically narrow pelvis is set to end in 1 or 2-stage of labor during the inspection early attempts

Hyperextension of the lower uterine segment

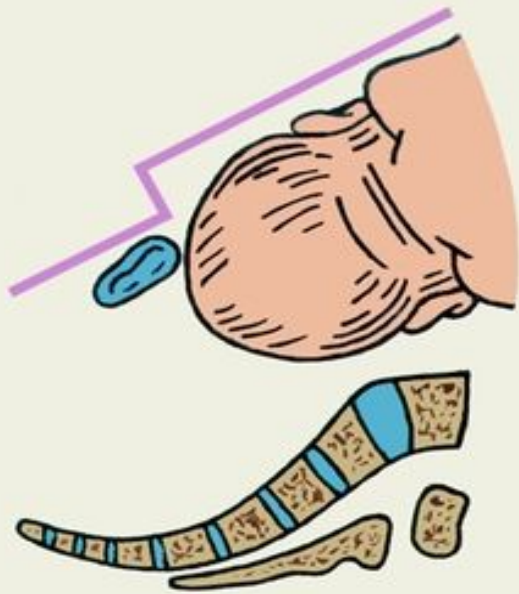Swelling of the cervix during the inspection

# SIGNS inappropriate:

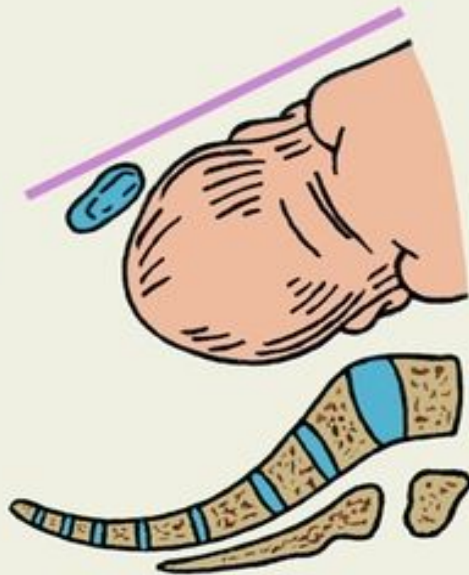Symptom Vasta

Symptom Tsangemeystra

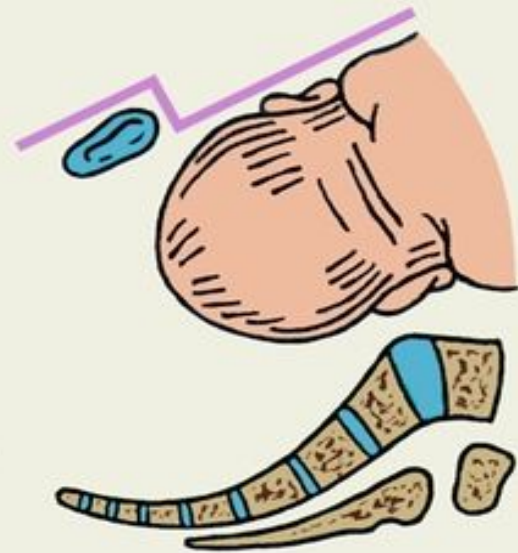Thinning of the lower uterine segment



(a)

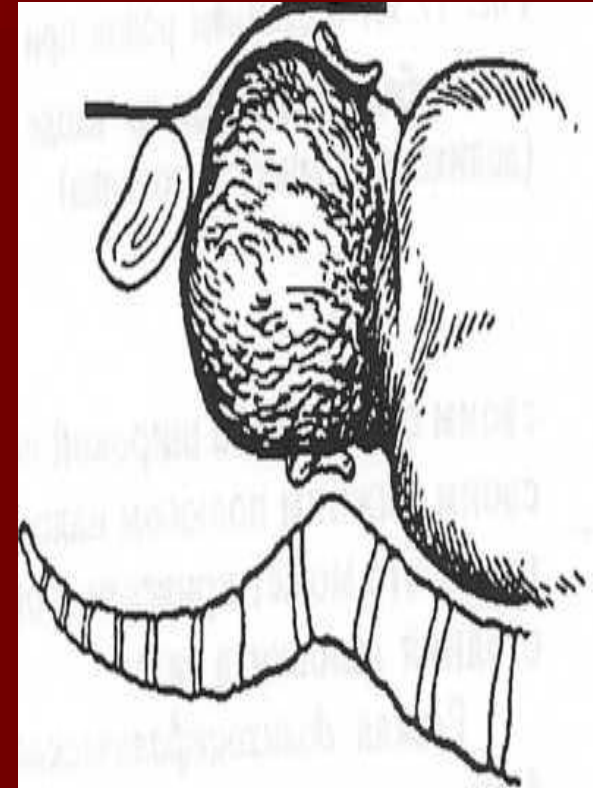
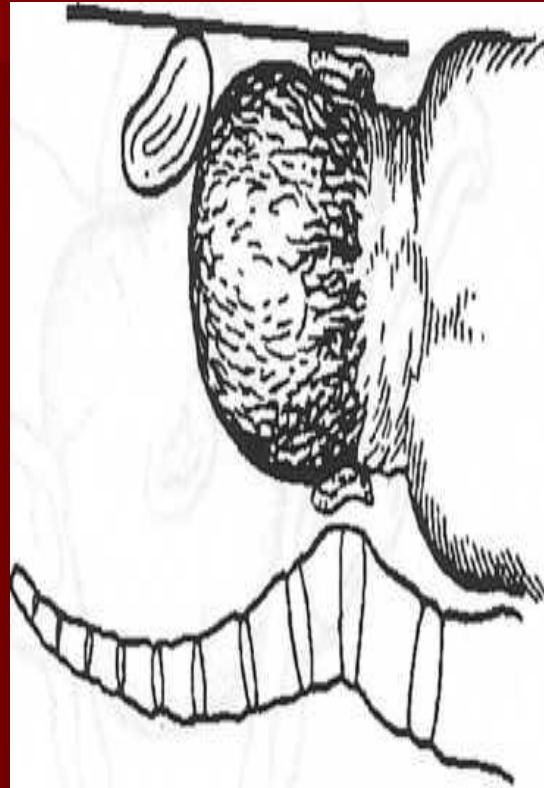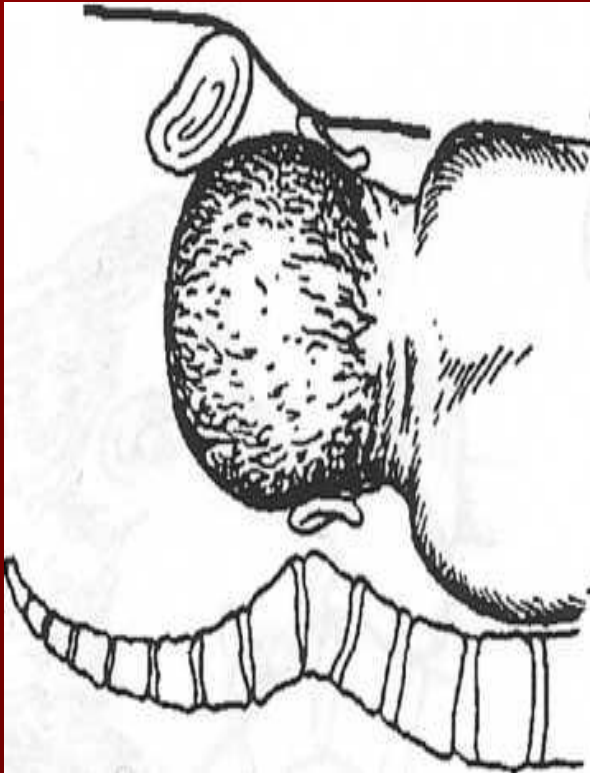


(b)



(B)

# Certain symptoms Vasta



# Delivery in clinically narrow pelvis:

1st degree - relative disparity -  
expectant management

2nd and 3rd degree - surgical  
delivery

# Prevention OUT

- In children: proper nutrition, hardening, prevention of rickets, prevention of childhood infections, correct posture
  - In adolescence, the right food, comfortable clothing netesnaya, injury prevention, exercise according to age

# Prevention clinically narrow pelvis

- Proper balanced nutrition during pregnancy
  - Restricting carbohydrates in the 2 half of pregnancy
  - Correct mode of work and rest
  - Monitoring the weight gain
  - Clinical supervision in the clinic for the position of the fetus