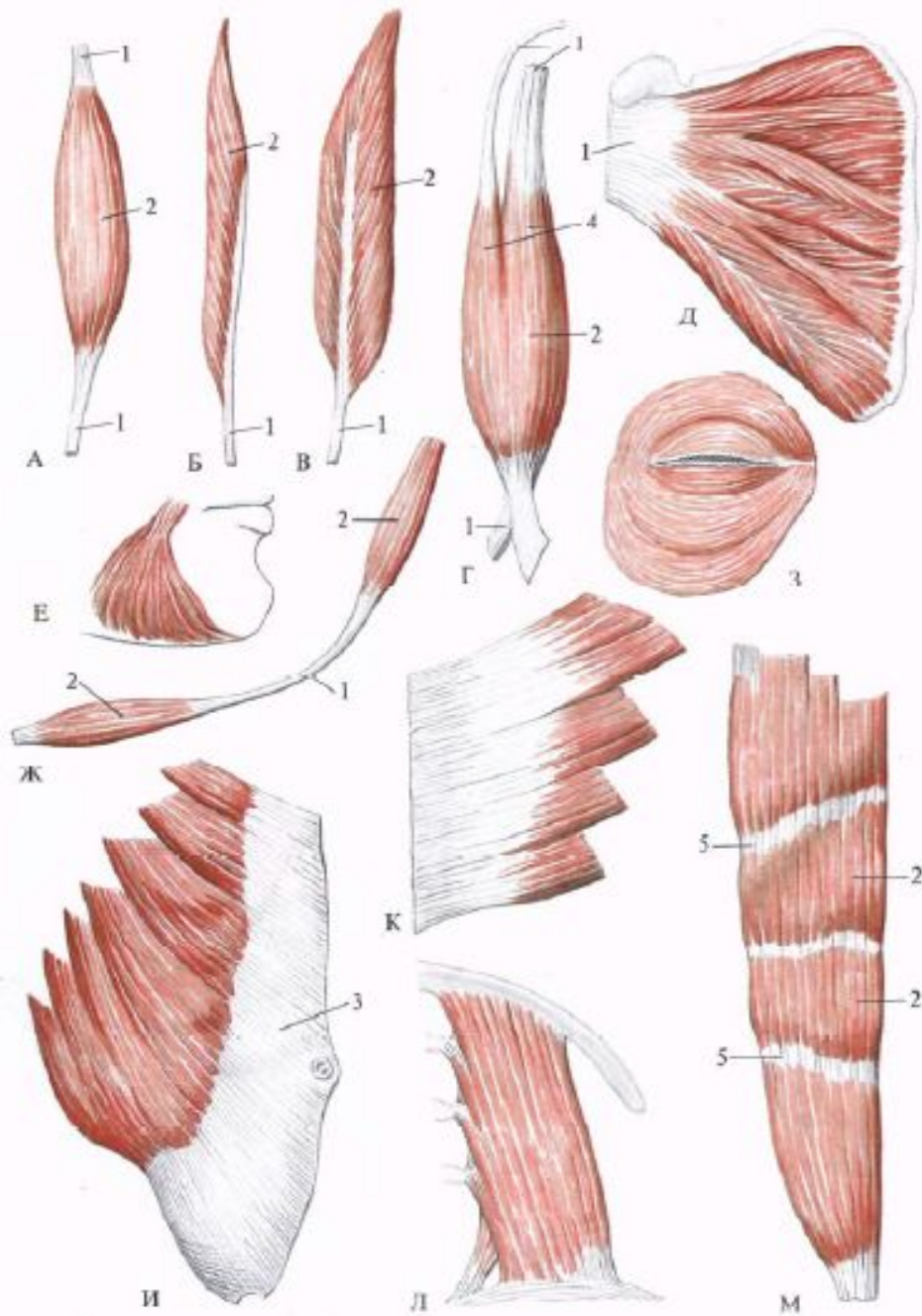
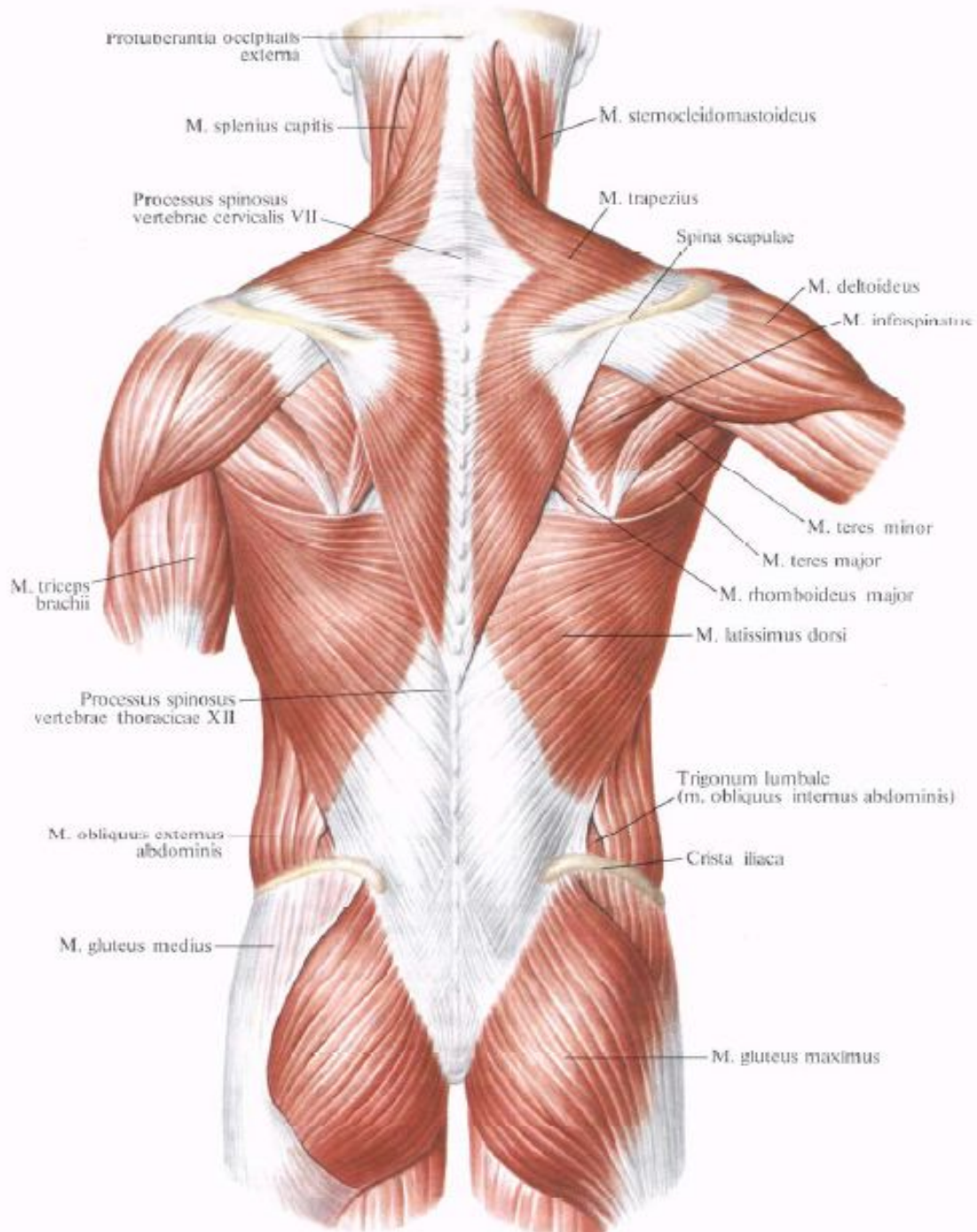
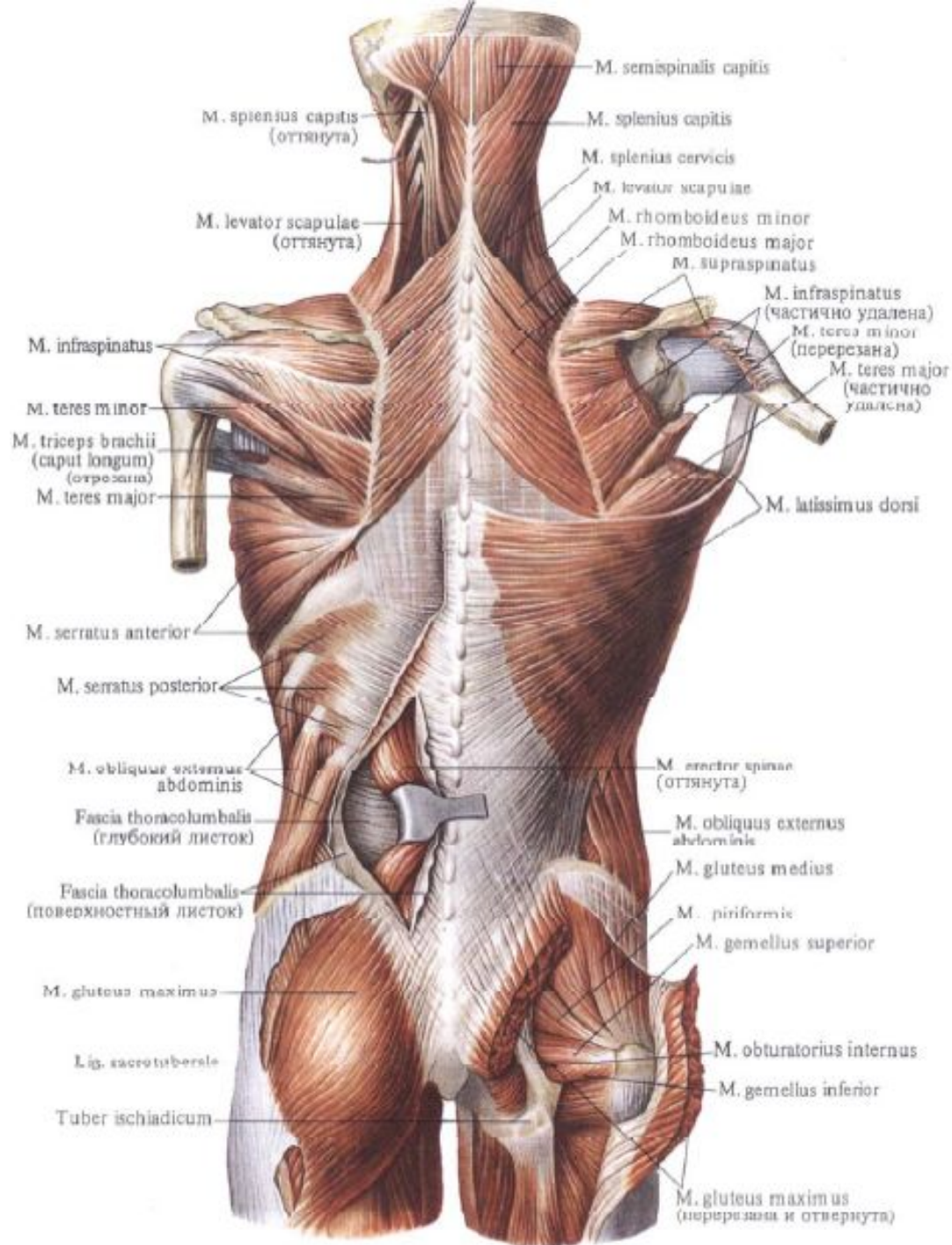
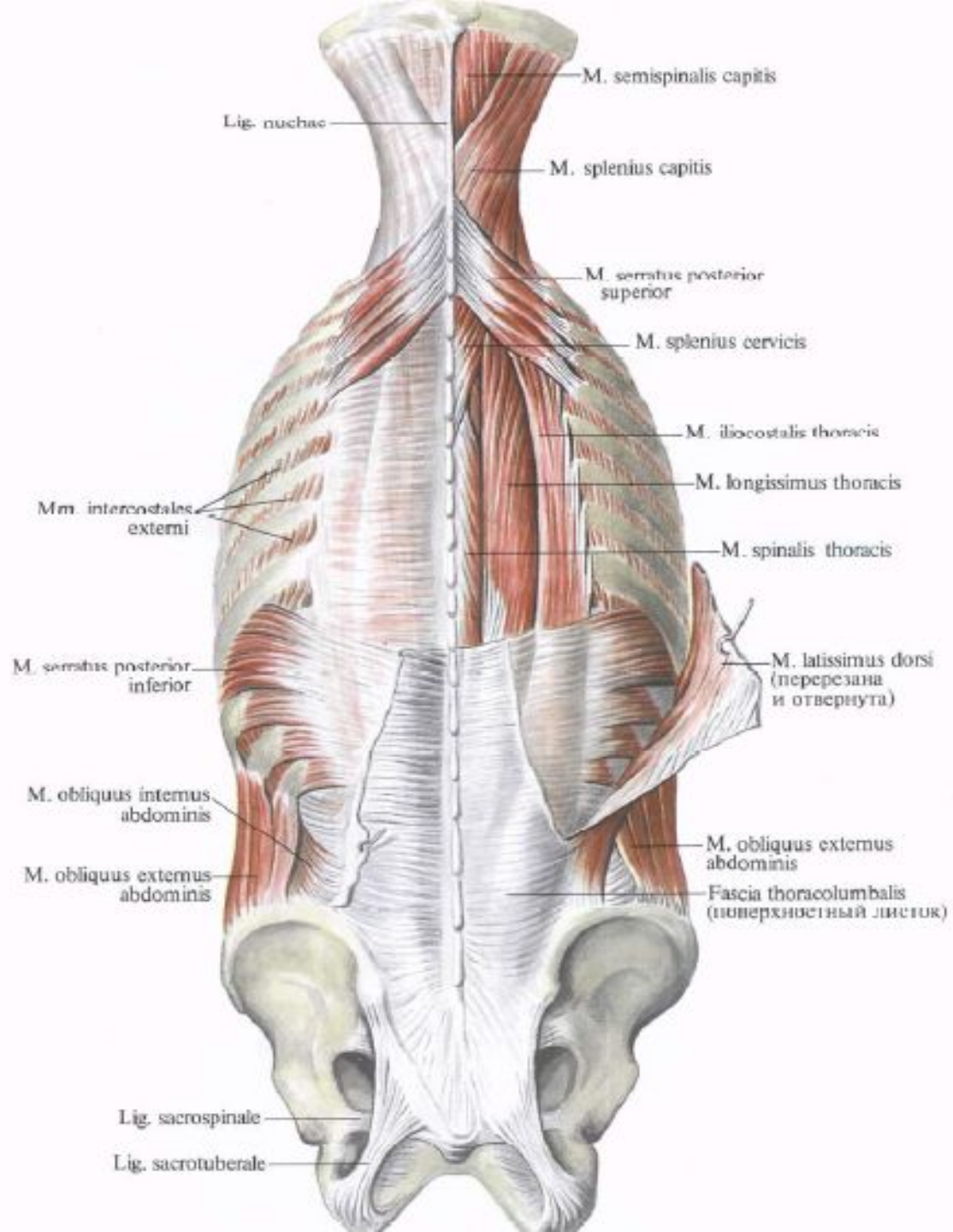


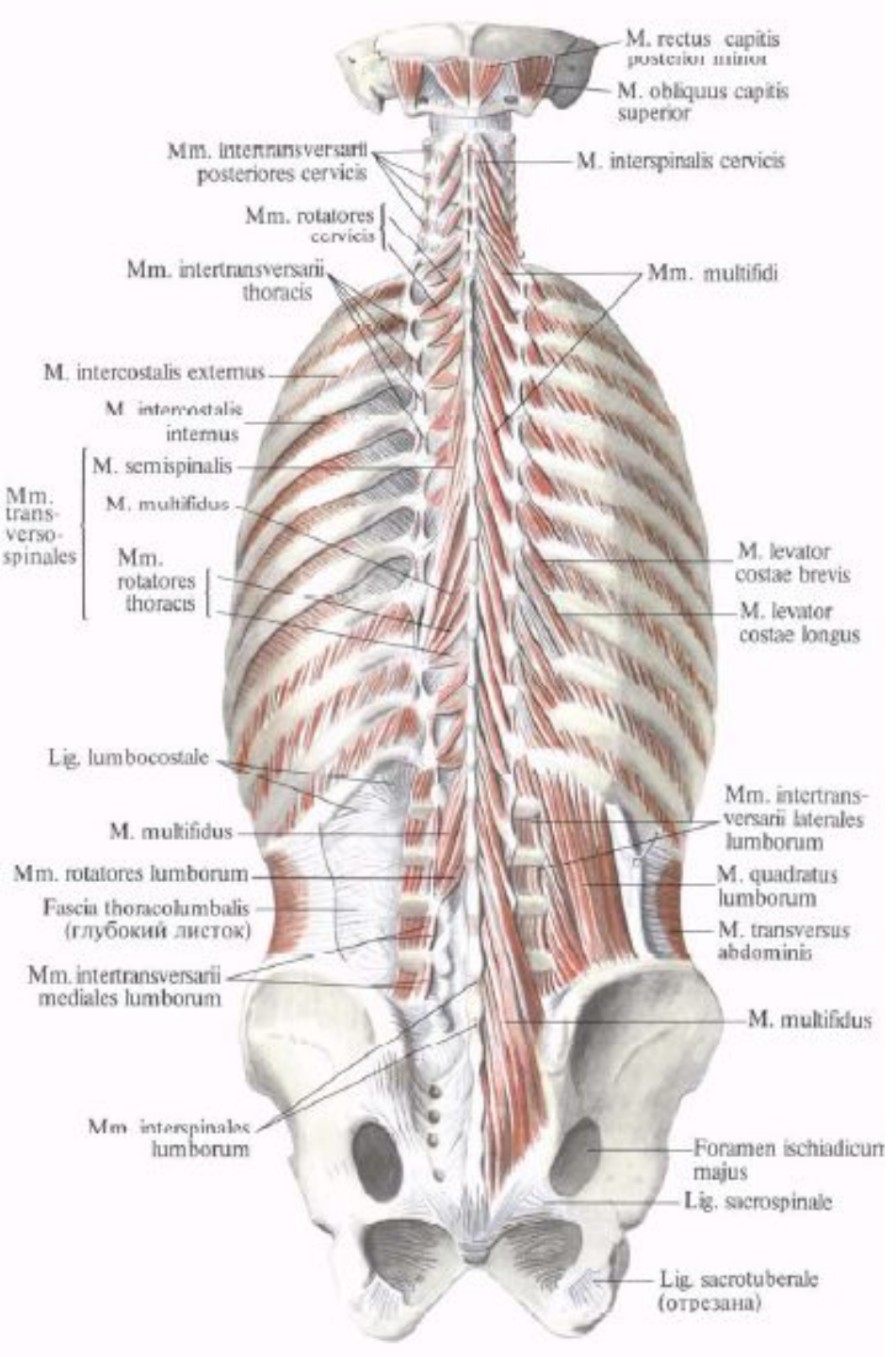
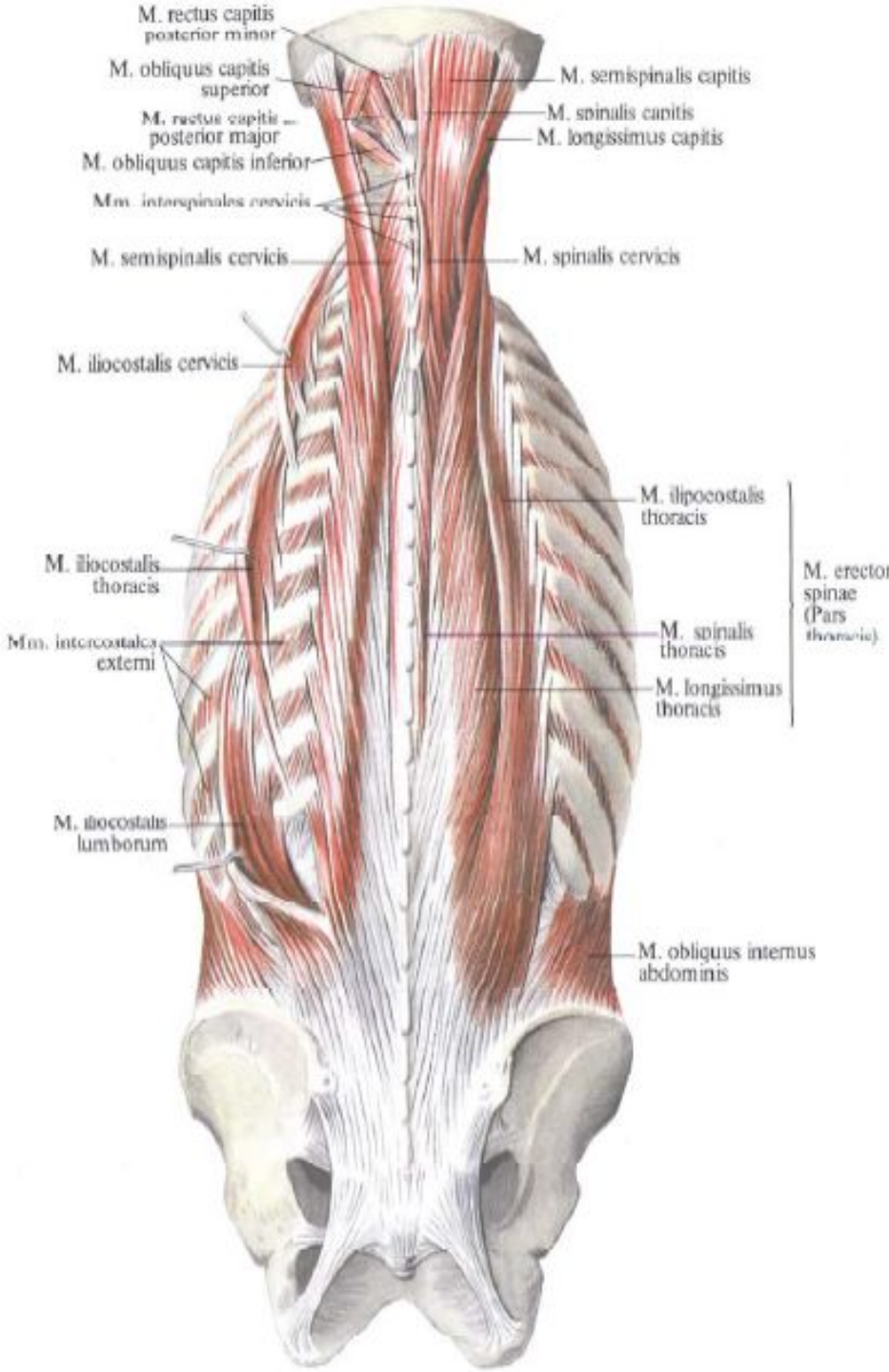
Миология

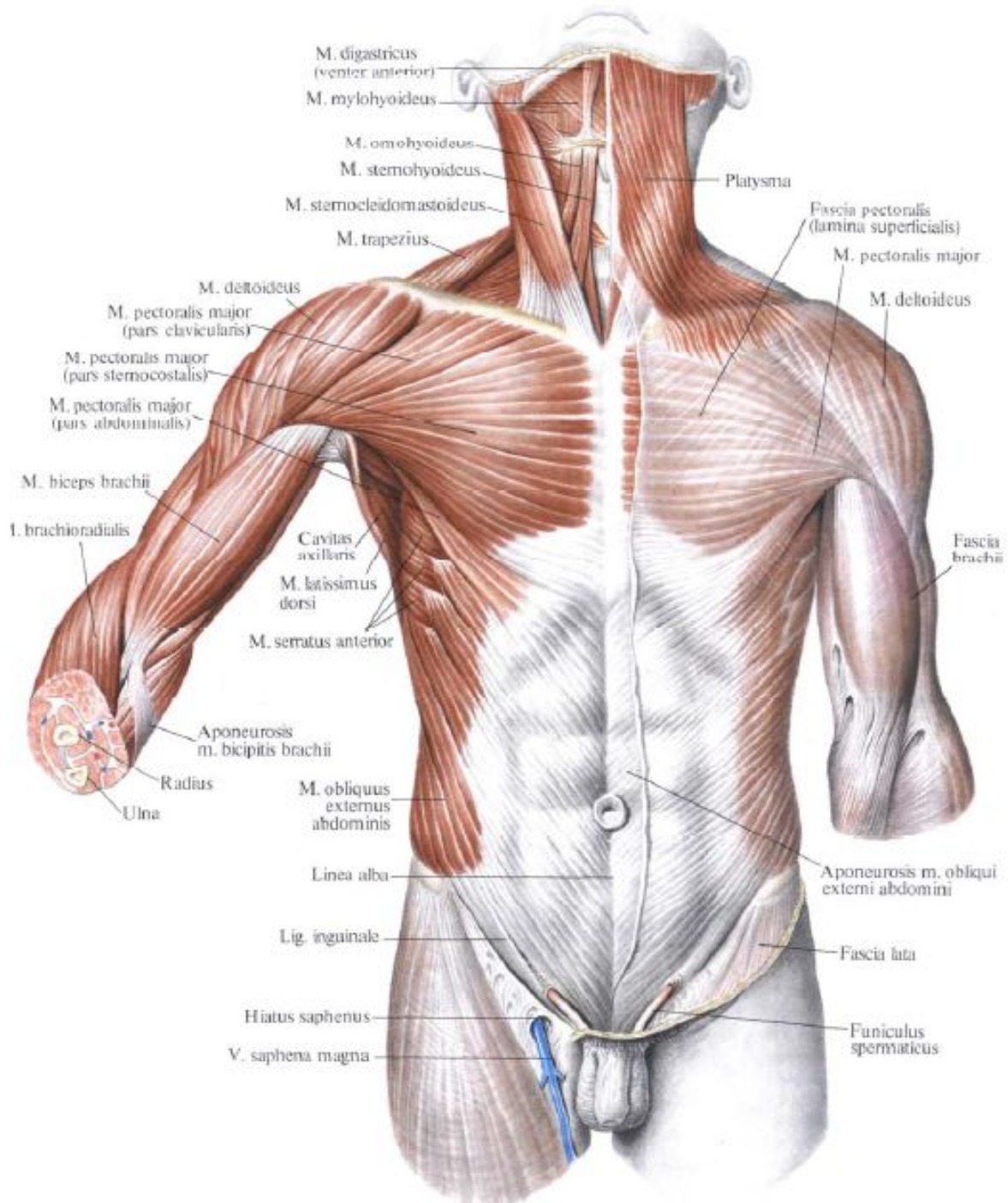


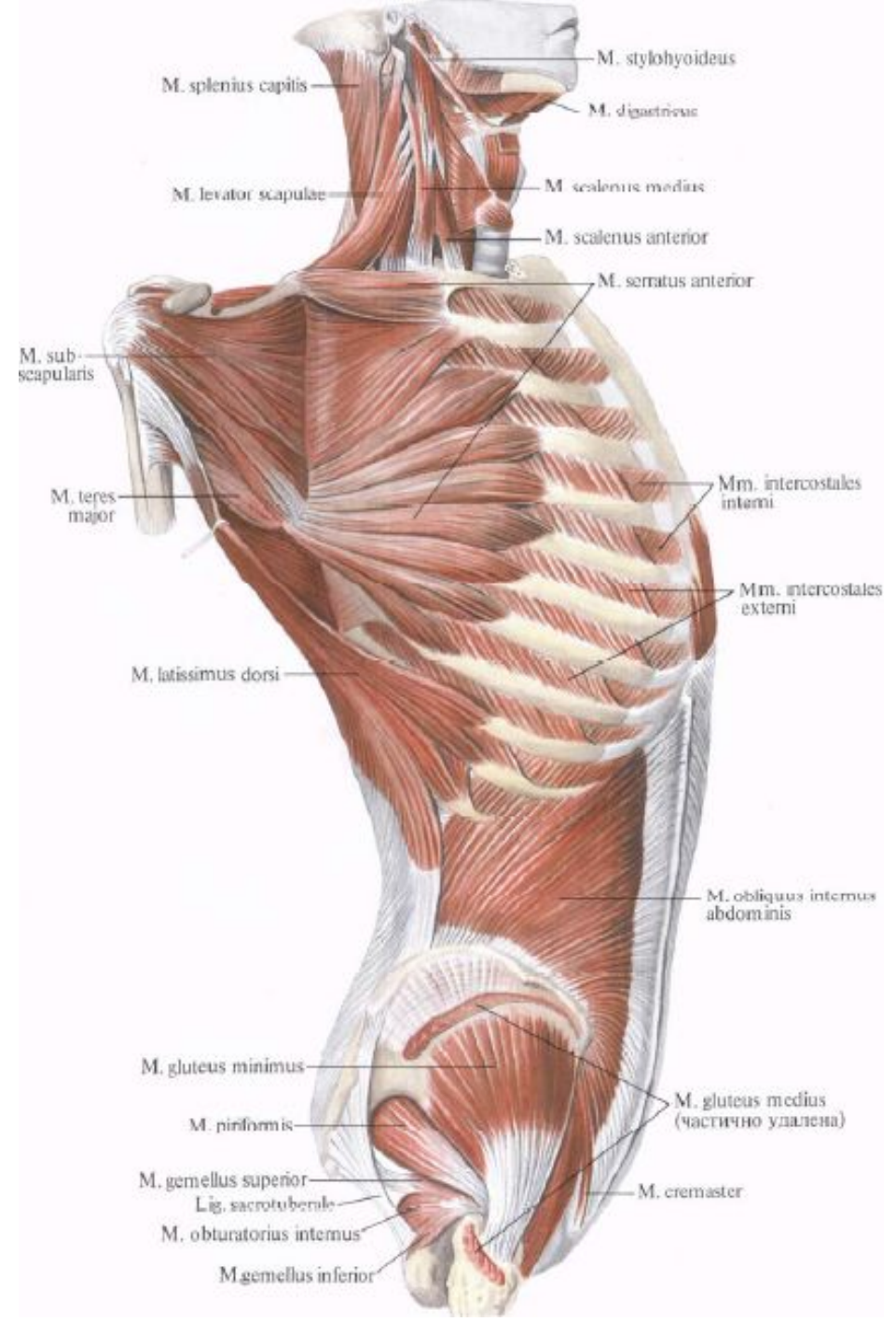
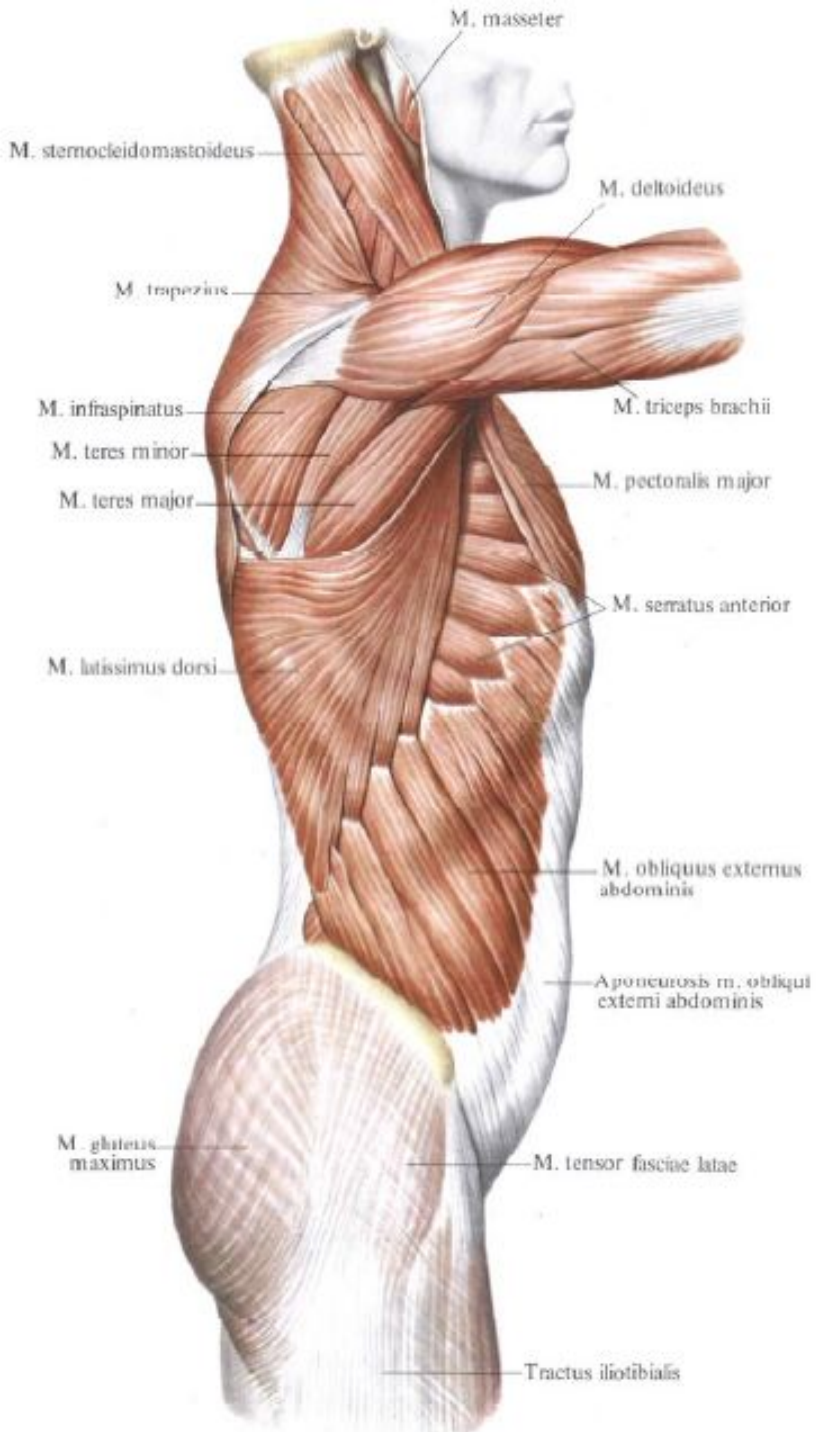


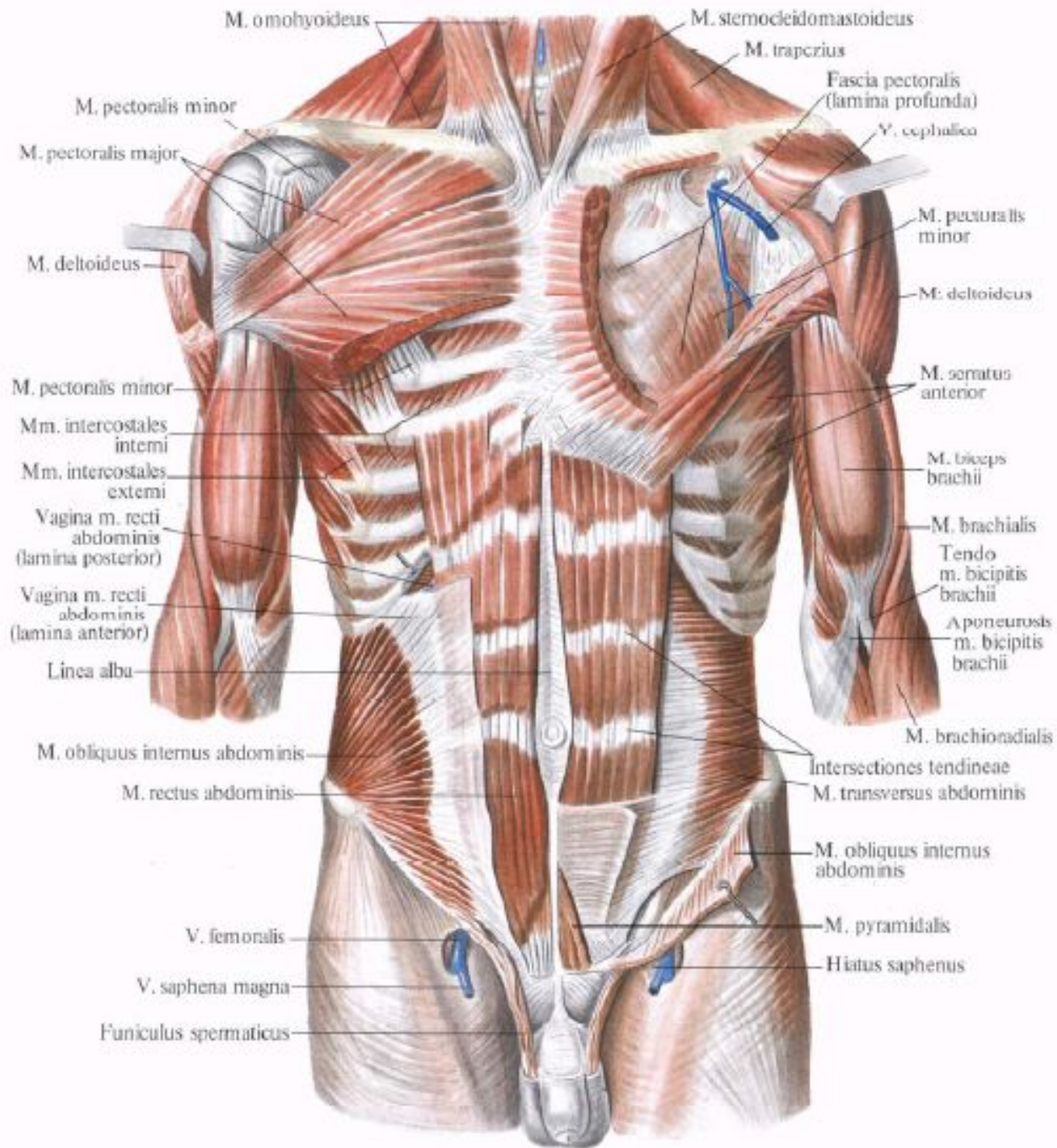


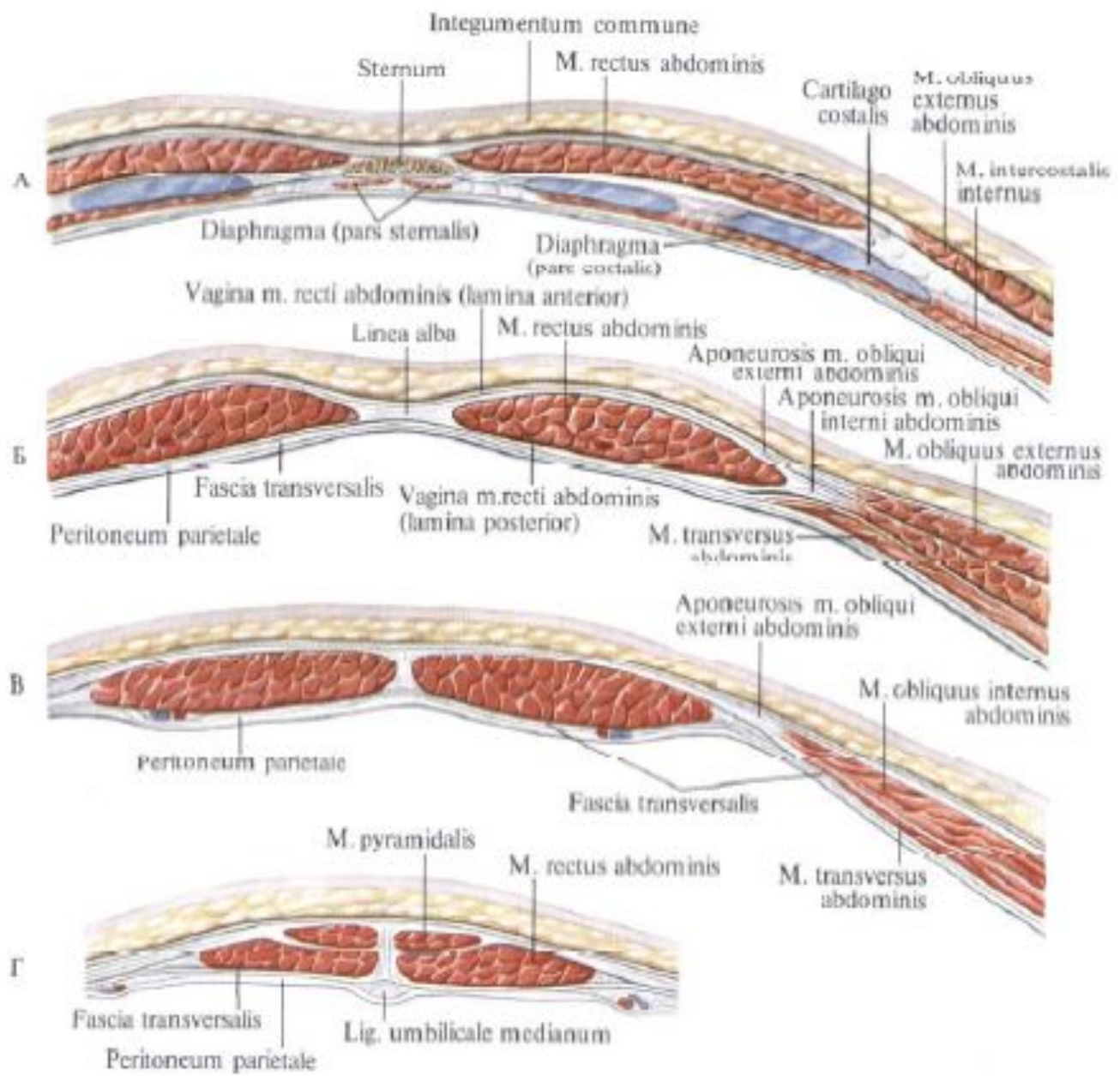


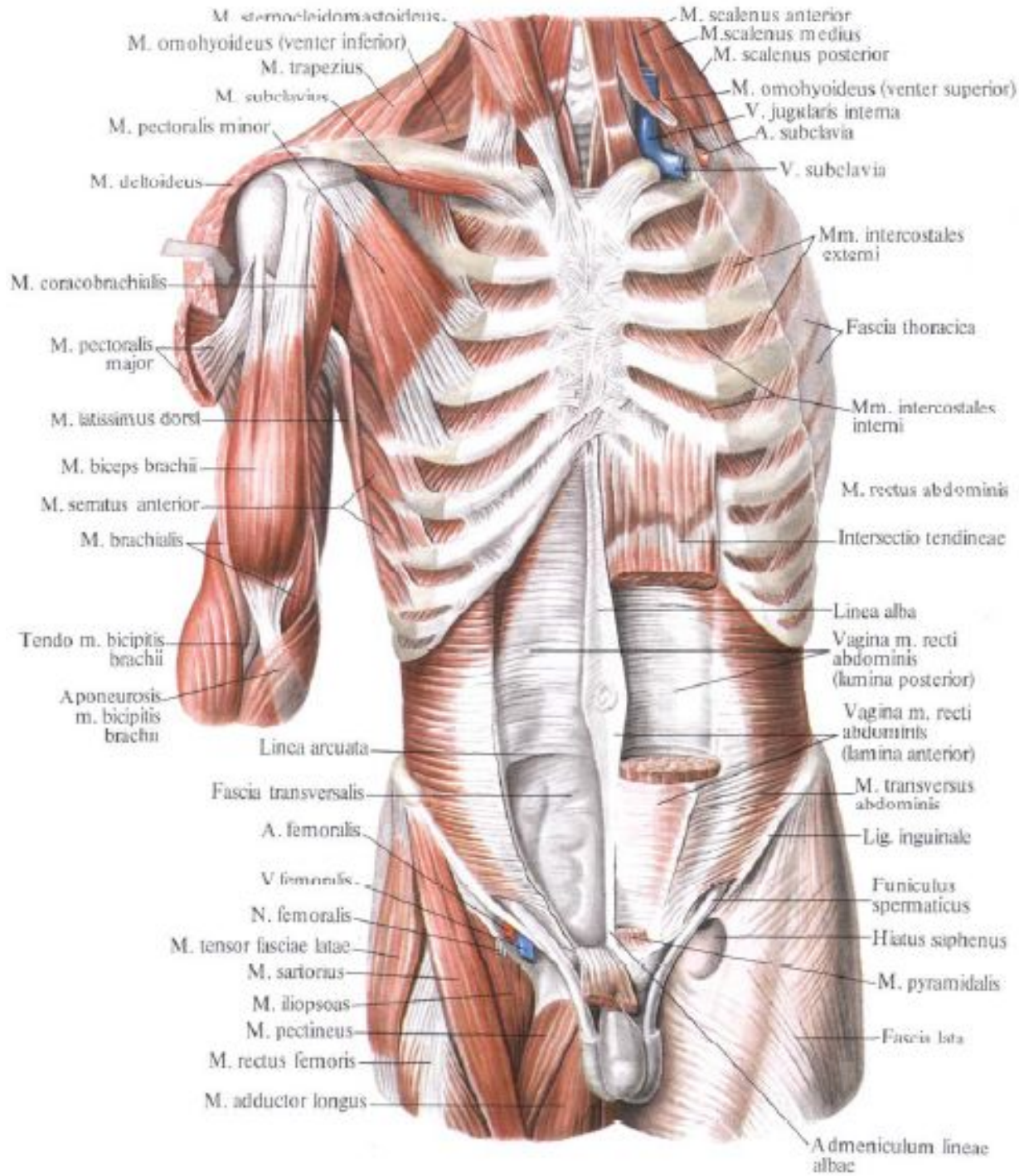






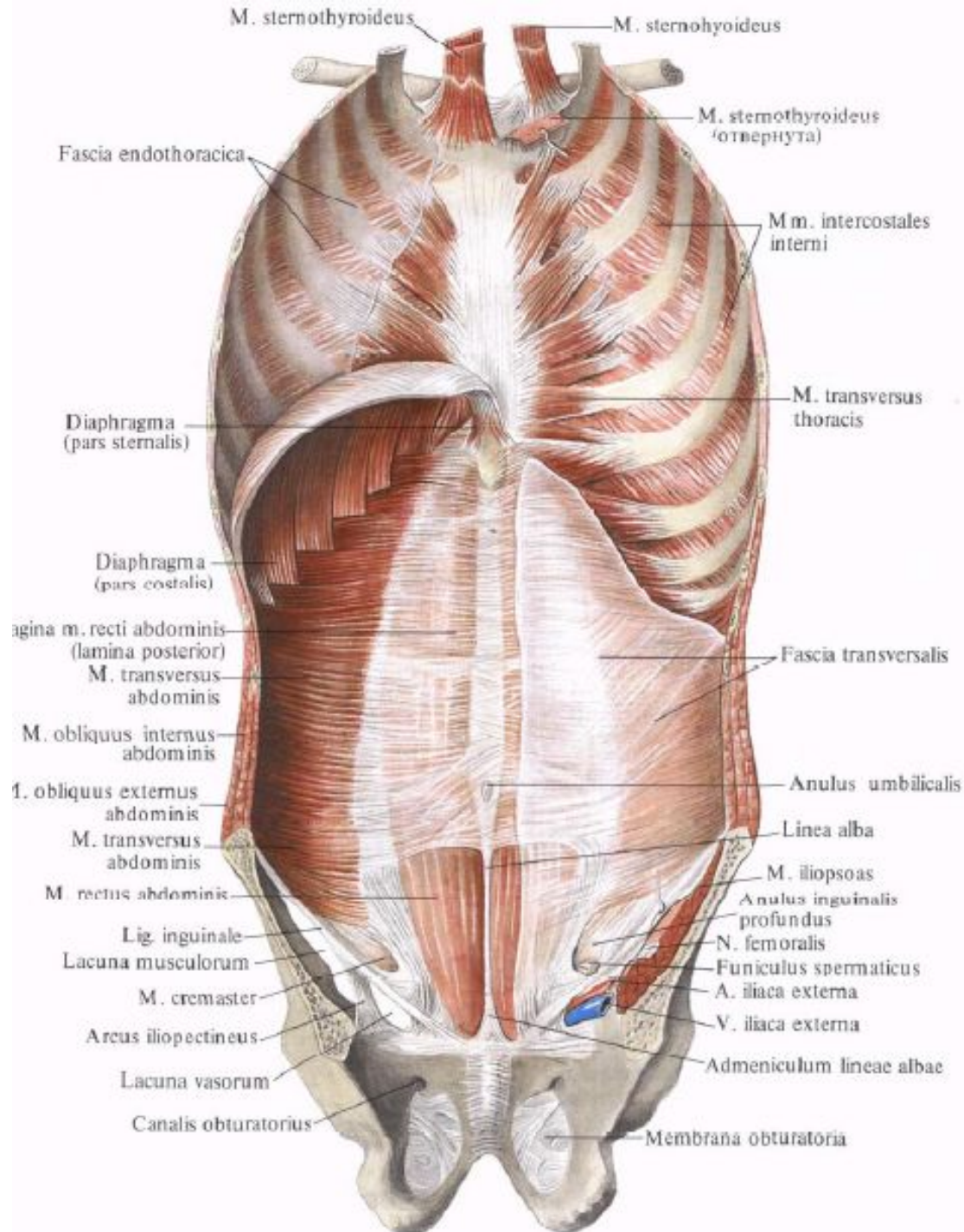


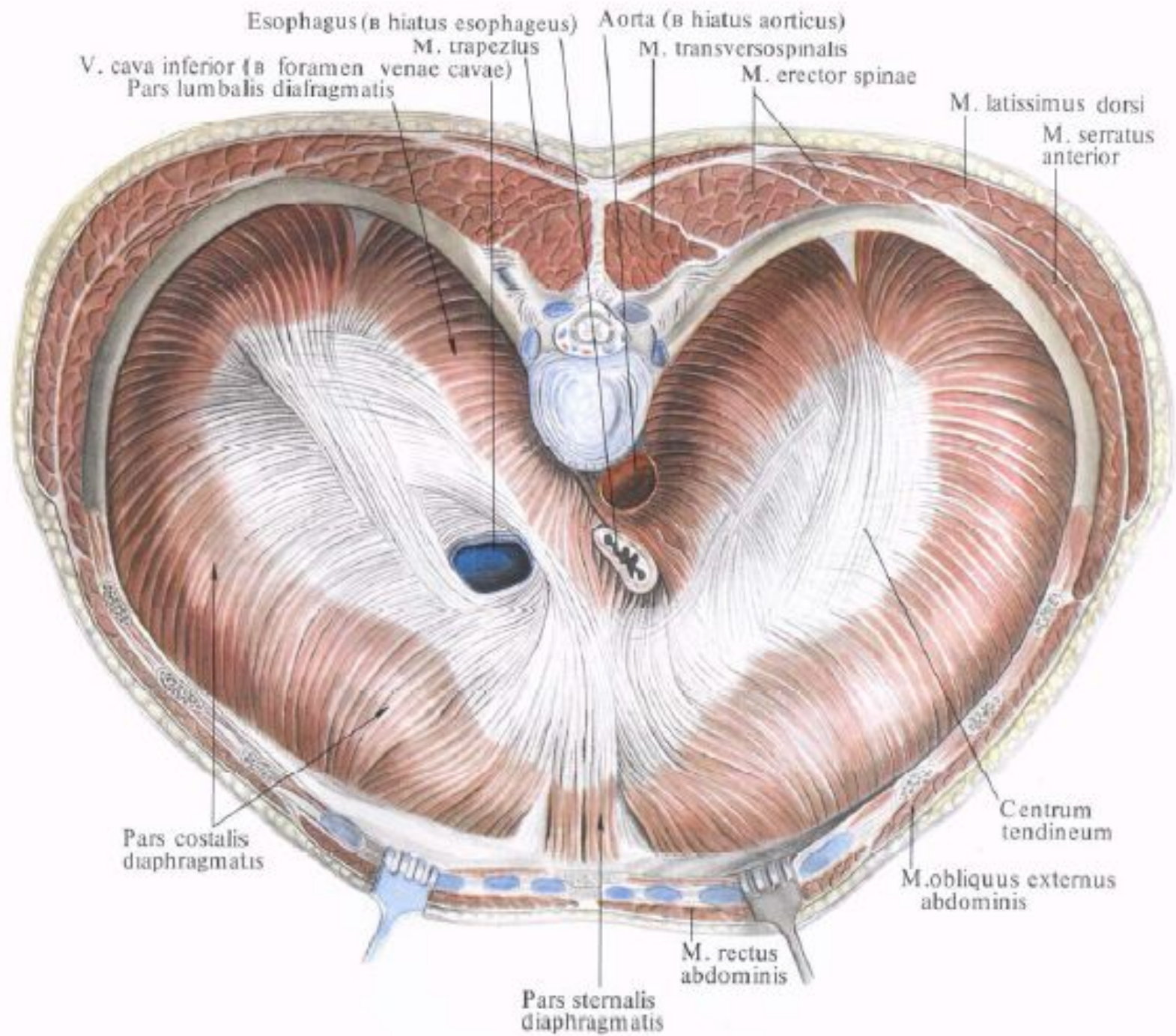


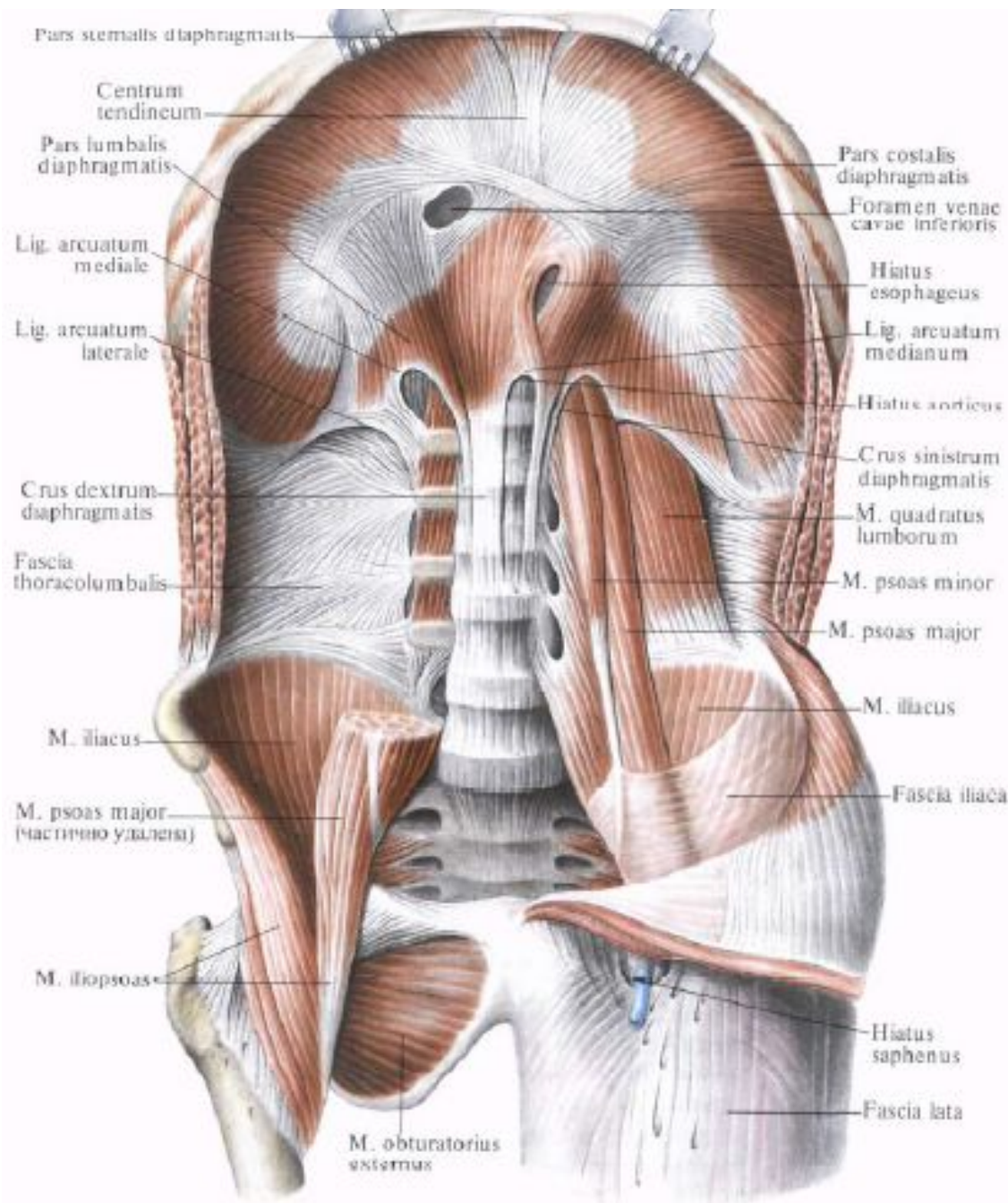


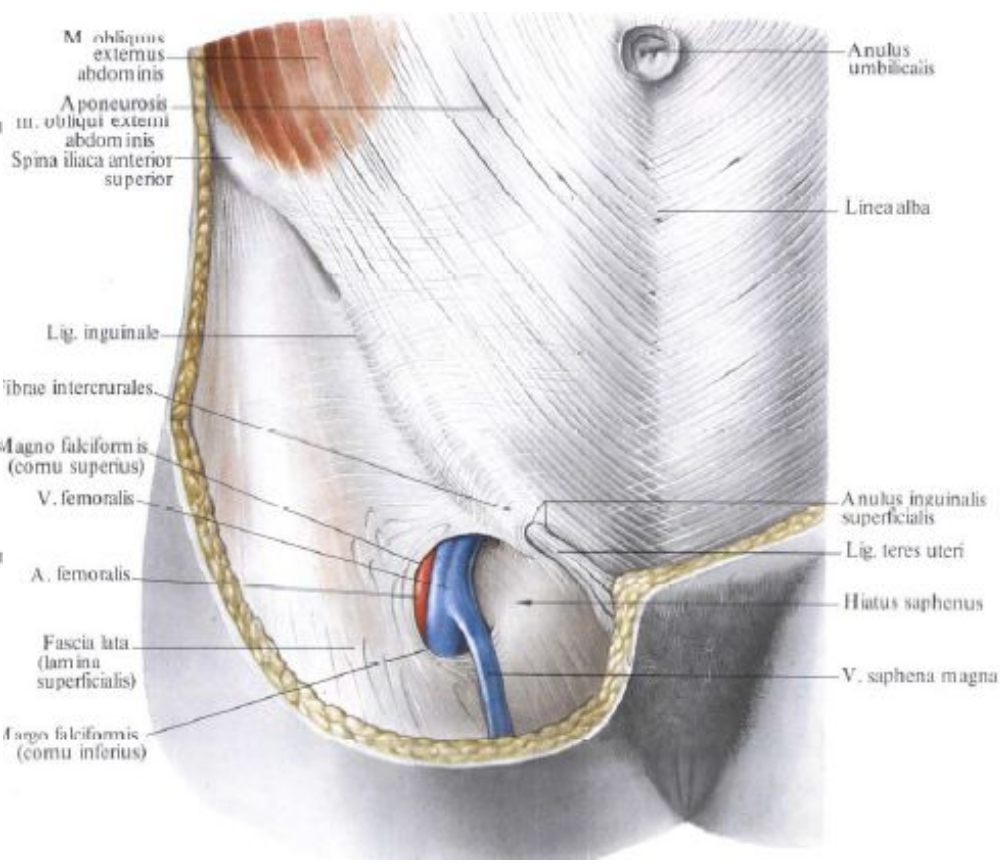
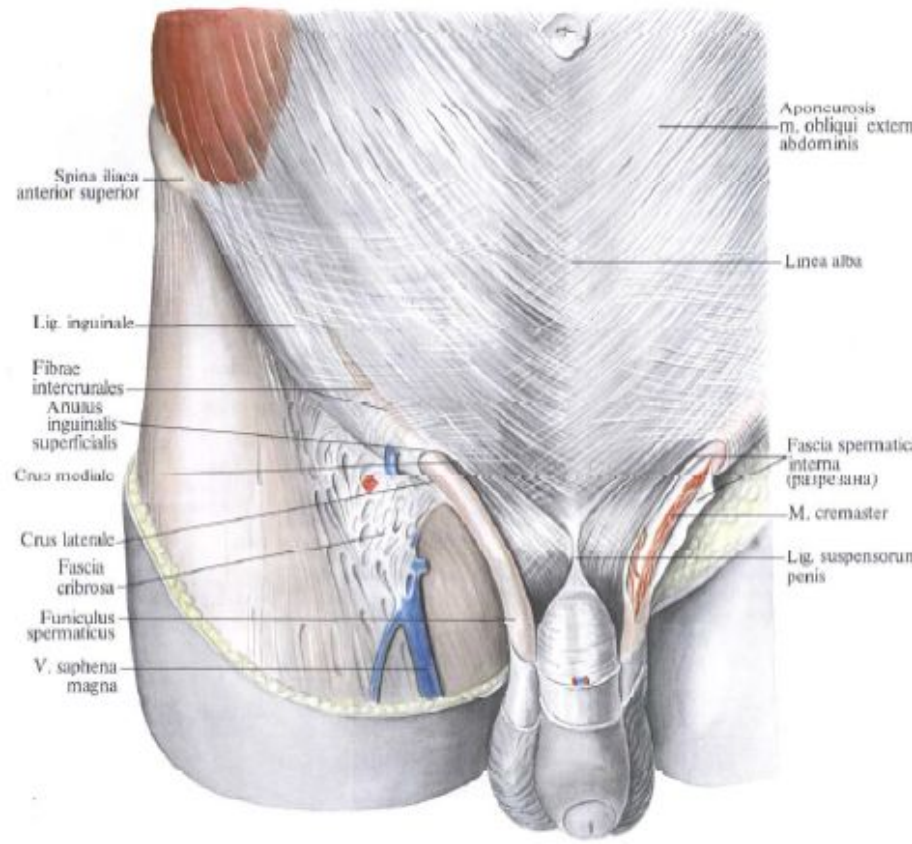
M. sternocleidomastoideus
 M. omohyoideus (venter inferior)
 M. trapezius
 M. subclavius
 M. pectoralis minor
 M. deltoideus
 M. coracobrachialis
 M. pectoralis major
 M. latissimus dorsi
 M. biceps brachii
 M. serratus anterior
 M. brachialis
 Tendo m. bicipitis brachii
 Aponeuosis m. bicipitis brachii
 Linea arcuata
 Fascia transversalis
 A. femoralis
 V. femoralis
 N. femoralis
 M. tensor fasciae latae
 M. sartorius
 M. iliopsoas
 M. pectineus
 M. rectus femoris
 M. adductor longus

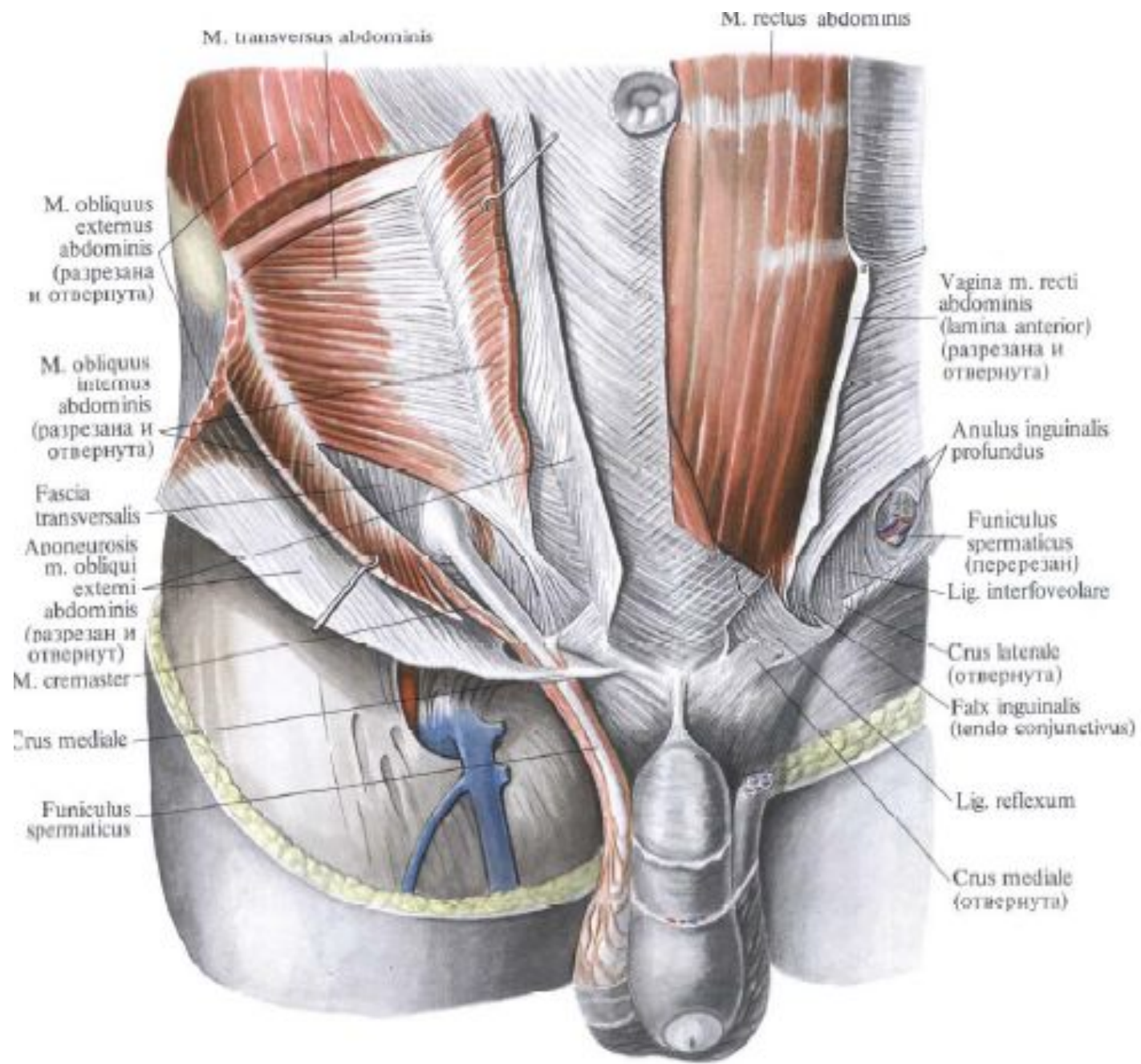
M. scalenus anterior
 M. scalenus medius
 M. scalenus posterior
 M. omohyoideus (venter superior)
 V. jugularis interna
 A. subclavia
 V. subclavia
 Mm. intercostales externi
 Fascia thoracica
 Mm. intercostales interni
 M. rectus abdominis
 Intersectio tendineae
 Linea alba
 Vagina m. recti abdominis (lamina posterior)
 Vagina m. recti abdominis (lamina anterior)
 M. transversus abdominis
 Lig. inguinale
 Funiculus spermaticus
 Hiatus saphenus
 M. pyramidalis
 Fascia lata
 Admeniculum lineae albae











M. transversus abdominis

M. rectus abdominis

M. obliquus externus abdominis (разрезана и отвернута)

M. obliquus internus abdominis (разрезана и отвернута)

Fascia transversalis
 Aponeurosis m. obliqui externi abdominis (разрезан и отвернут)
 M. cremaster

Crus mediale

Funiculus spermaticus

Vagina m. recti abdominis (lamina anterior) (разрезана и отвернута)

Anulus inguinalis profundus

Funiculus spermaticus (перерезан)

Lig. interfoveolare

Crus laterale (отвернута)

Falx inguinalis (tendo conjunctivus)

Lig. reflexum

Crus mediale (отвернута)

