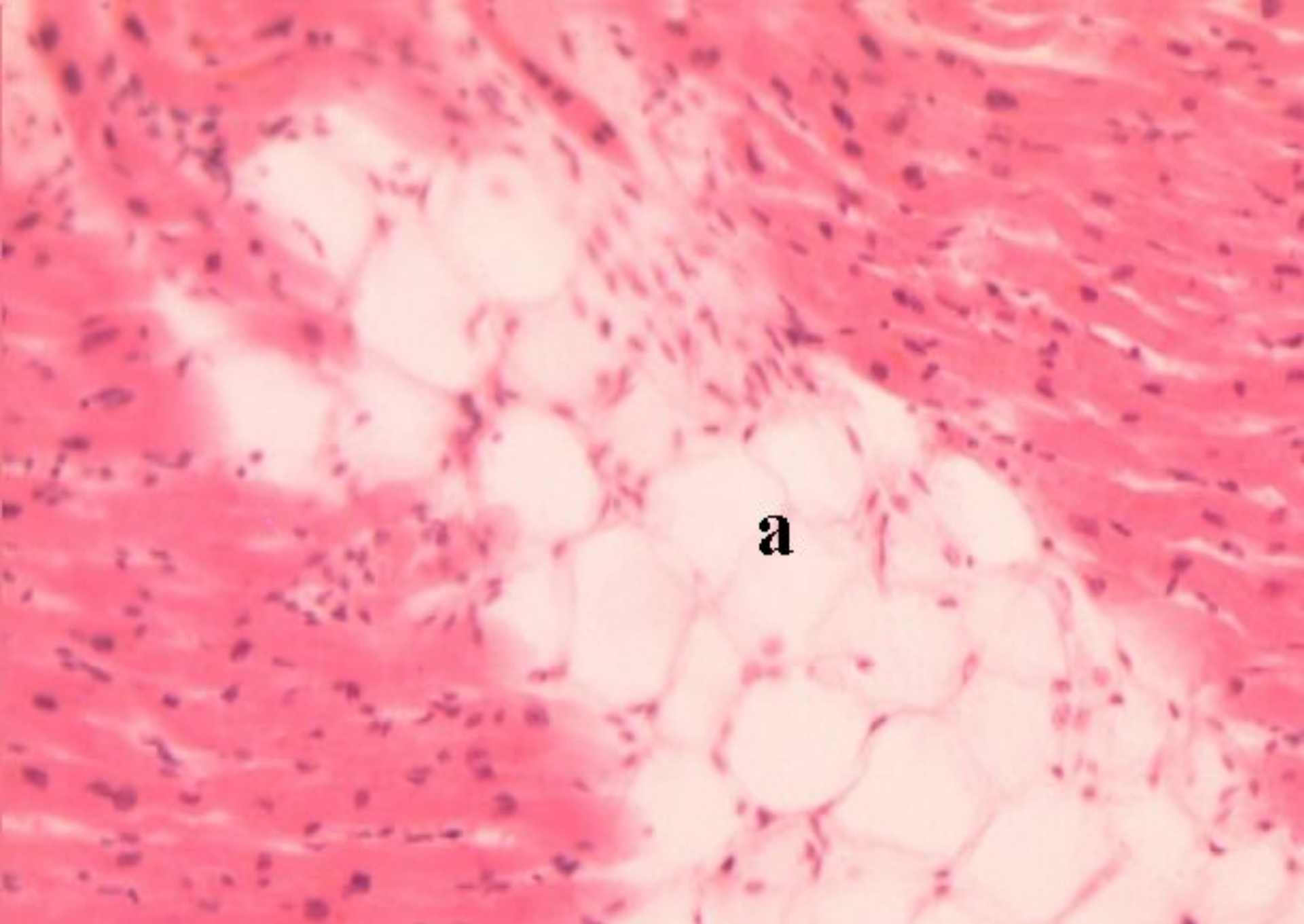


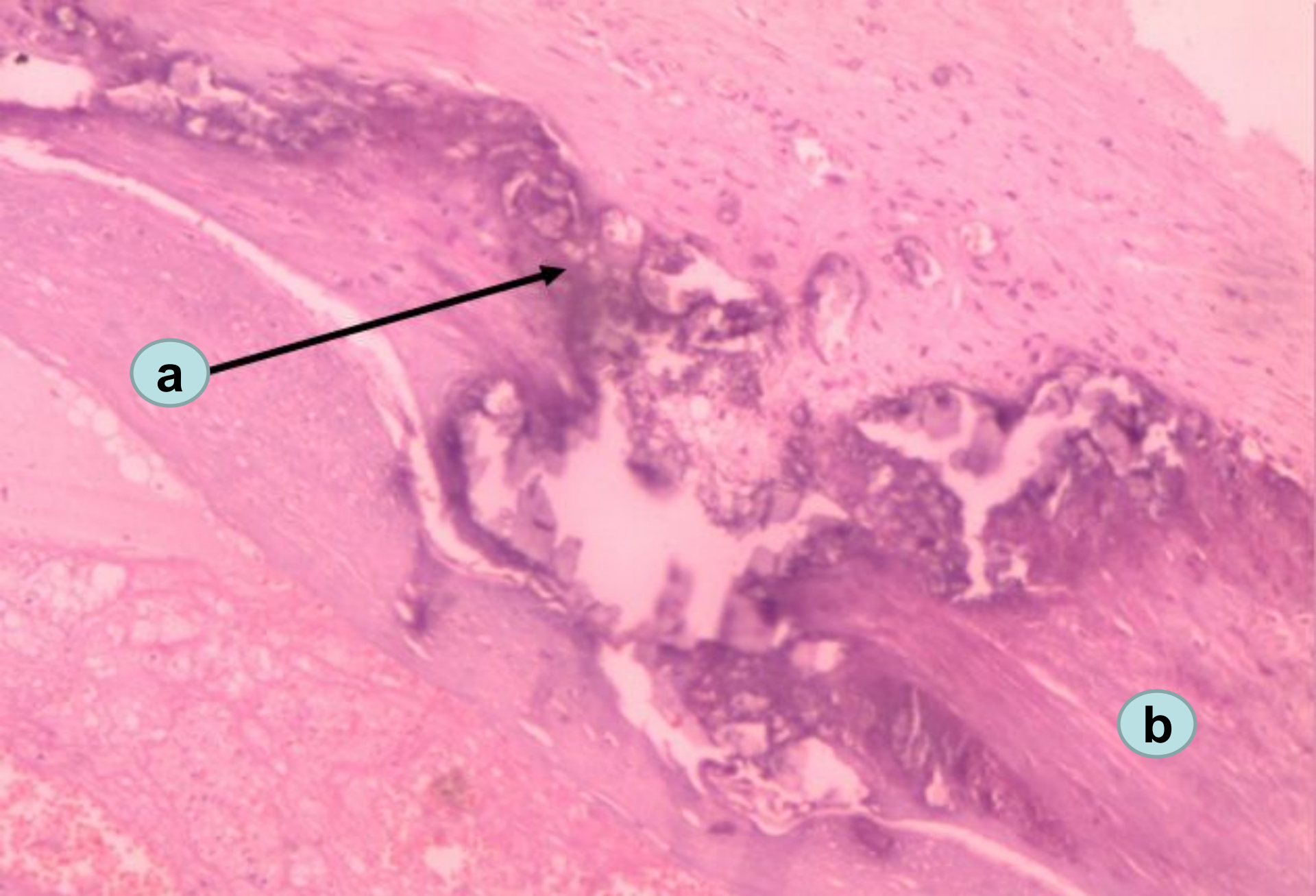
**Topic № 3. Extracellular protein accumulations (degenerations):  
mucoid swelling, hyalinosis. Amyloidosis. Intracellular lipid  
accumulations (degenerations): obesity, cachexy. Parenchymatous  
carbohydrate degenerations.**

**Prepared by  
d.m.s. Shabdarbaeva D.M.**



**Heart obesity**

**a – fat vacuoles between myocardial fibers**

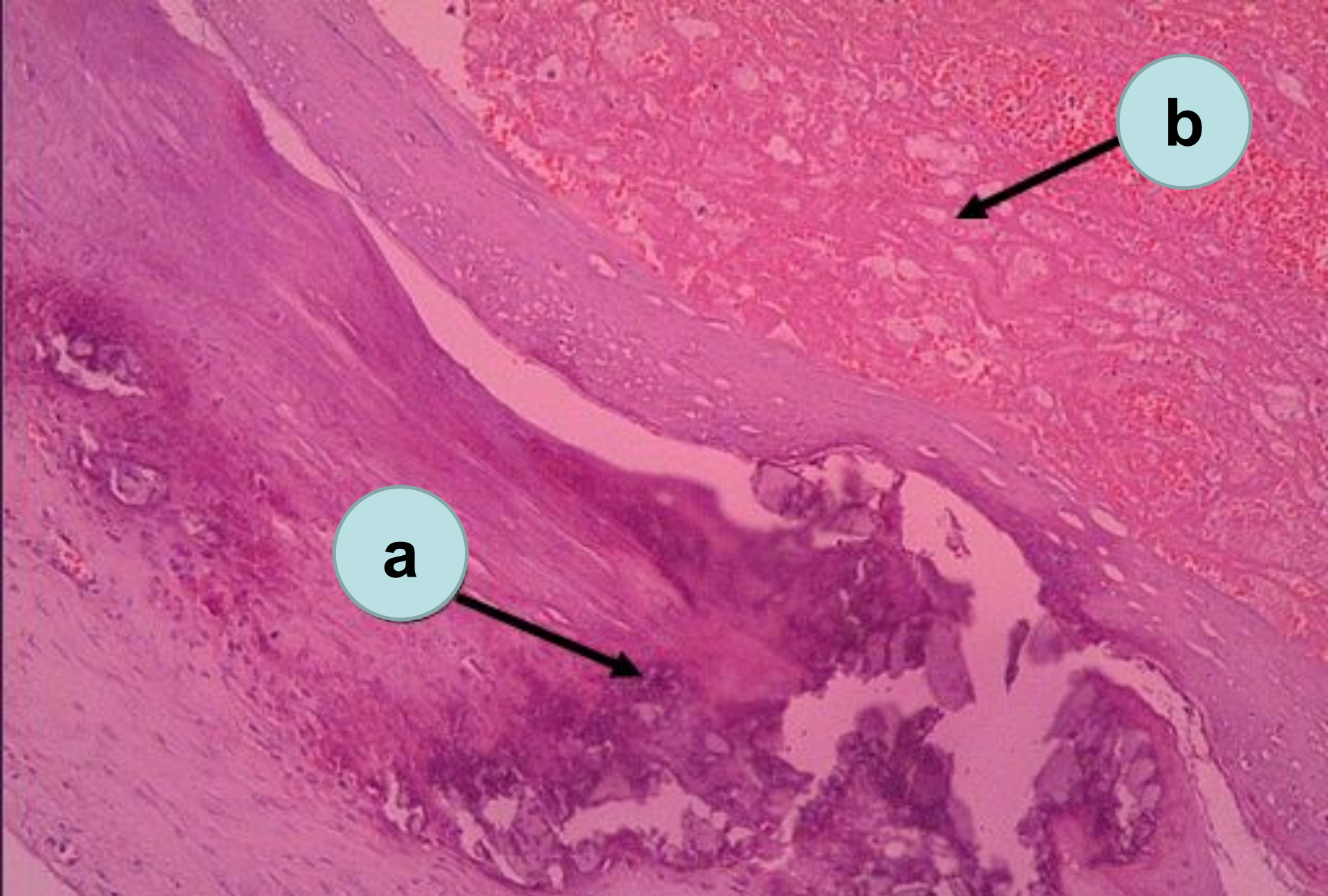


**Atherosclerosis of iliac artery with calcinosis**

**a – deposition of calcium salts (blue colored area)**

**b – growth of connective tissue**



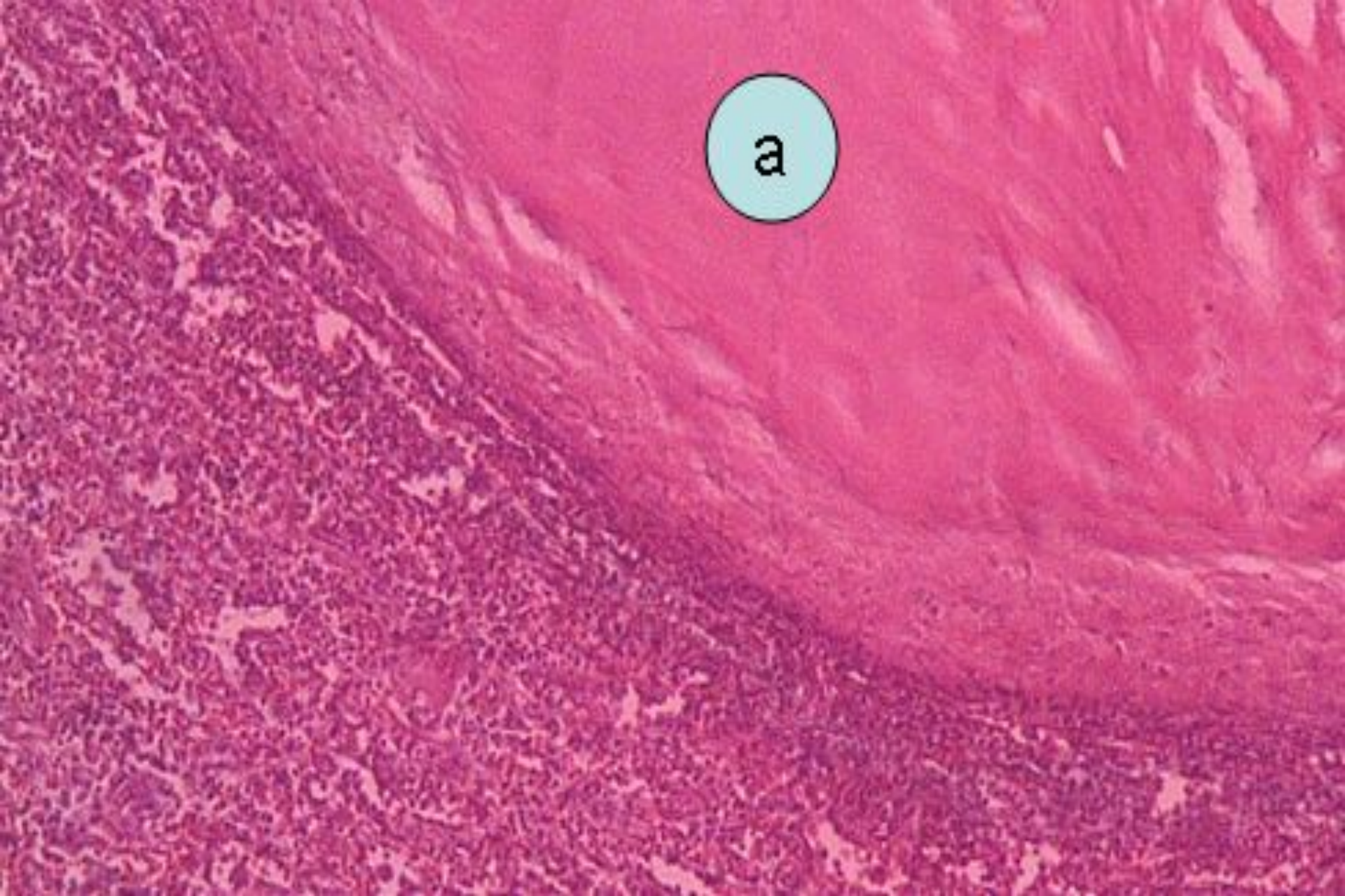


**Atherosclerosis & calcification of iliac artery with thrombosis**

**a – salts of calcium (blue color)**

**b - thrombus**





Hyalinosis of the capsule of spleen

a – homogenous hyaline resemble substance, stained in pink color