

Main Case

NIRVE Rounds



Miguel García-Grimshaw
PGY-6 Neurology Resident

National Institute of Medical Science and Nutrition Salvador Zubirán, Mexico City

October 1, 2020

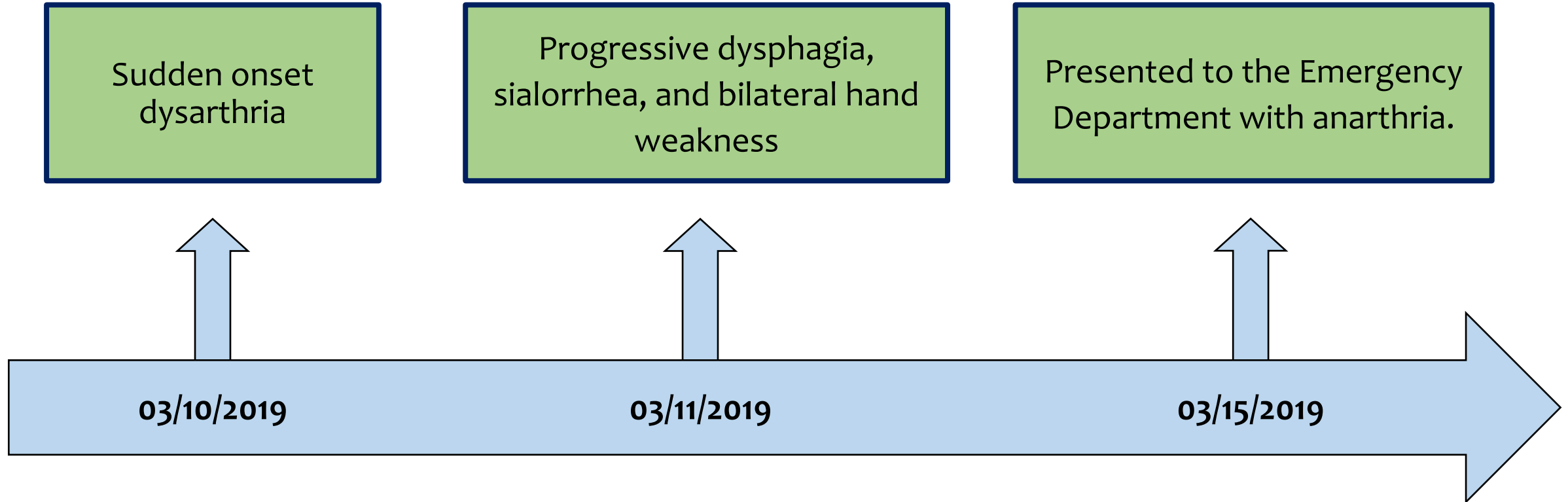


History

- **Previously healthy 34-year-old right-handed woman.**
 - Mexico city resident.
 - Housewife.
 - Non-smoker.
- **Past medical history:**
 - Uneventful cesarean section one month before admission.
 - Allergies, substance abuse, use of contraceptive drugs, and history of abortions were denied.
 - No recent history of vaccination.
- **Family history:**
 - There was no family history of chronic, systemic, infectious, or neurological diseases.



Presentation



Relevant negatives: Fever, vertigo, headache, altered mental status, visual or sensory disturbance



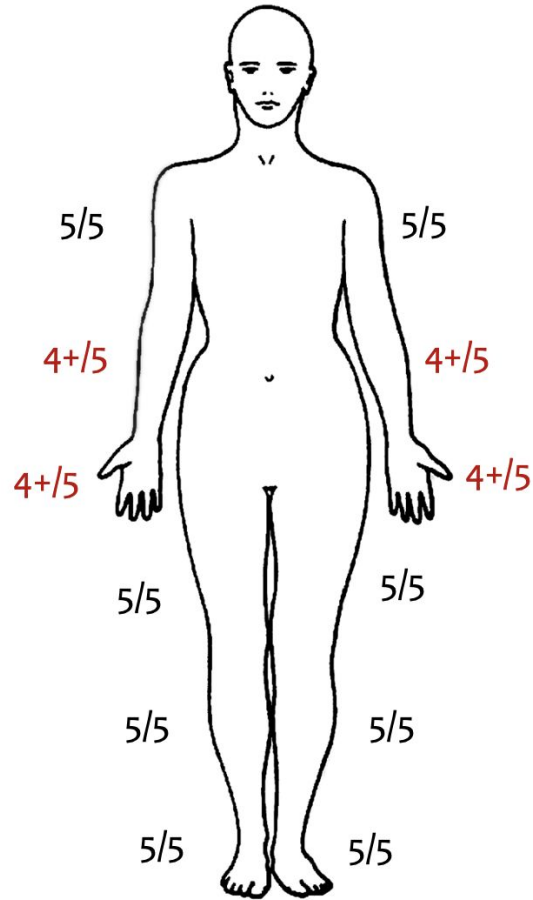
Neurological examination

Vital signs: BP: 112/75 mmHg, BR: 14 bpm, HR: 76 bpm, Temperature: 97.7 °F (36.5 °C), SpO₂ on room air 98%.

- **Mental status:** Alert and orientated.
- **Language:** Anarthric, auditory, and reading comprehension were intact, able to communicate with signs and by handwriting.
 - Reading comprehension was evaluated by asking the patient to follow written orders and tasks.
- **Cranial nerves:** (Video will be presented)
 - V: Sensory: Normal; Motor: Limited mouth opening and unable to make lateral movements of the jaw. Absent jaw jerk reflex.
 - VII: Bilateral central facial diplegia.
 - IX and X: Unable to swallow with a bilateral normal gag reflex.
 - XII: Unable to protrude or make lateral movements of the tongue.
- **Cerebellum:** Normal.
- **Extrapyramidal signs:** None.
- **Gait:** Normal.
- **Abnormal movements:** None.
- Prominent automatic-voluntary dissociation, characterized by preserved yawning and smiling.

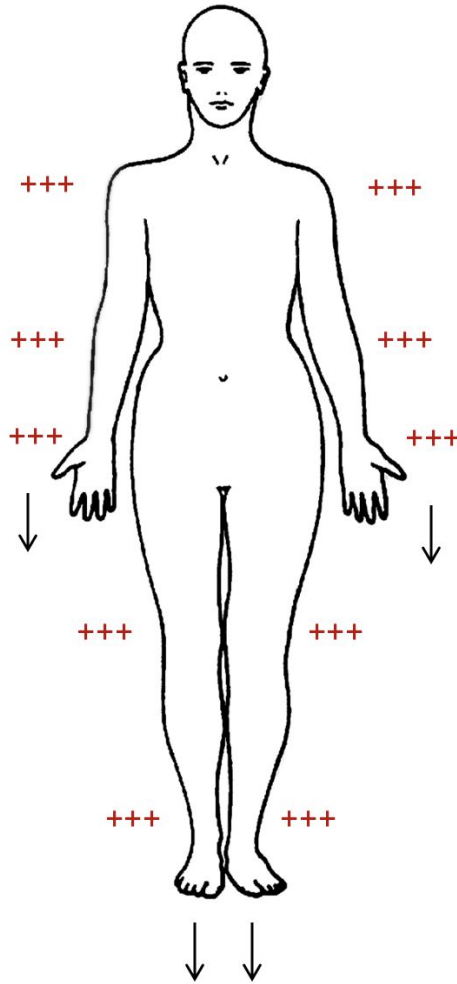
Neurological examination

Strength

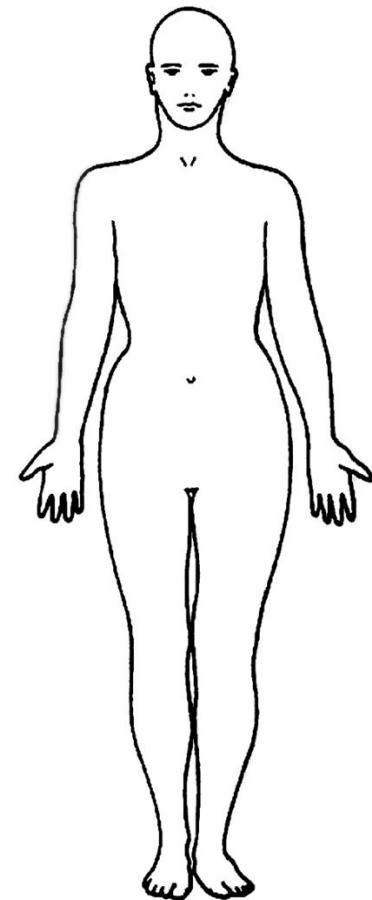


Muscle tone: Normal

Reflexes



Sensory Examination



Normal